



## OPEN ACCESS

# The genetic landscape and clinical implications of vertebral anomalies in VACTERL association

Yixin Chen,<sup>1</sup> Zhenlei Liu,<sup>1</sup> Jia Chen,<sup>1</sup> Yuzhi Zuo,<sup>1</sup> Sen Liu,<sup>1,2</sup> Weisheng Chen,<sup>1</sup> Gang Liu,<sup>1</sup> Guixing Qiu,<sup>1,2</sup> Philip F Giampietro,<sup>3</sup> Nan Wu,<sup>1,2</sup> Zhihong Wu<sup>2,4</sup>

For numbered affiliations see end of article.

## Correspondence to

Dr Nan Wu, Department of Orthopedic Surgery, Peking Union Medical College Hospital, Peking Union Medical College and Chinese Academy of Medical Sciences, No.1 Shuaifuyuan, Beijing 100730, China; Beijing Key Laboratory for Genetic Research of Skeletal Deformity, China; dr.wunan@pumch.cn

Dr Zhihong Wu, Department of Central Laboratory, Peking Union Medical College Hospital, Peking Union Medical College and Chinese Academy of Medical Sciences, No.1 Shuaifuyuan, Beijing 100730, China; Beijing Key Laboratory for Genetic Research of Skeletal Deformity, China; wuzh3000@126.com

Received 30 November 2015  
Revised 3 March 2016  
Accepted 17 March 2016  
Published Online First  
15 April 2016



Open Access  
Scan to access more  
free content



CrossMark

To cite: Chen Y, Liu Z, Chen J, et al. *J Med Genet* 2016;**53**:431–437.

## ABSTRACT

VACTERL association is a condition comprising multisystem congenital malformations, causing severe physical disability in affected individuals. It is typically defined by the concurrence of at least three of the following component features: vertebral anomalies (V), anal atresia (A), cardiac malformations (C), tracheo-oesophageal fistula (TE), renal dysplasia (R) and limb abnormalities (L). Vertebral anomaly is one of the most important and common defects that has been reported in approximately 60–95% of all VACTERL patients. Recent breakthroughs have suggested that genetic factors play an important role in VACTERL association, especially in those with vertebral phenotypes. In this review, we summarised the genetic studies of the VACTERL association, especially focusing on the genetic aetiology of patients with vertebral anomalies. Furthermore, genetic reports of other syndromes with vertebral phenotypes overlapping with VACTERL association are also included. We aim to provide a further understanding of the genetic aetiology and a better evidence for genetic diagnosis of the association and vertebral anomalies.

## OVERVIEW OF VACTERL ASSOCIATION

VACTERL association is a condition with multisystem congenital malformations: Vertebral anomalies (V), anal atresia (A), cardiac malformation (C), tracheo-oesophageal fistula (TE) with or without oesophageal atresia, renal dysplasia (R) and limb abnormalities (L).<sup>1–2</sup> It was first named as VATER (without 'C' and 'L') association in 1973.<sup>3</sup> The prevalence of VACTERL/VATER association is between 1/7000 and 1/40 000.<sup>4–5</sup>

As there is no available objective laboratory test for its diagnosis, VACTERL association is diagnosed totally based on the clinical manifestations mentioned above. Most clinicians and researchers require the presence of at least three component features for diagnosis. Besides, due to its heterogeneous phenotype and the abundance of overlapping defects of other syndromes, VACTERL association is typically considered a diagnosis of exclusion<sup>5–8</sup> with no clear evidence for an alternative or overlapping diagnosis such as Coloboma, Heart anomaly, Atresia of choanae, Retardation of mental and somatic development, Genital hypoplasia, Ear abnormalities (CHARGE) syndrome, DiGeorge syndrome and Pallister–Hall syndrome. The presence of other features not typically seen in VACTERL association may suggest other disorders. Thus, a physical examination and family history are essential to rule out potentially overlapping diagnoses. It is worth mentioning that 5–10% patients with Fanconi anaemia

(FA) have birth defects meeting the diagnosis of VACTERL association with hydrocephalus (VACTERL-H).<sup>9–10</sup> It is suggested that FA with VACTERL-H should be treated separately from the VACTERL association because of the core characteristics of FA such as haematological anomalies and skin pigmentary changes, the different frequencies of VACTERL-associated phenotypes and the prognosis and therapeutic intervention.<sup>10–11</sup>

Although the clinical criteria for VACTERL association appear to be straightforward, the overlapping in either clinical manifestation or genetic finding is challenging for clinicians and geneticists. The *CHD7* gene mutation, which is proved to be associated with CHARGE syndrome, may also be found in patients diagnosed with VACTERL association, even CHARGE syndrome is clinically excluded.<sup>12</sup> Besides, most of the conditions listed are monogenic disorders. Careful genetic evaluation may help ruling out these conditions. In this review, we listed the related monogenic diseases that share two more overlapping manifestations and their genetic findings (table 1). We propose that (1) these syndromes as well as these candidate genes should be considered in diagnostic and genetic studies in VACTERL association; and (2) VACTERL syndrome remains a diagnosis of exclusion following a thoughtful clinical evaluation and consideration of genetic testing for overlapping syndromes.

Prior studies have estimated that 90% of the patients diagnosed with VACTERL association had three or fewer phenotypes (referred to as VACTERL-like association) and <1% of patients had all six anomalies.<sup>4</sup> Although the frequency of the six clinical features (CFs) varies, vertebral anomalies is the most common observation in many cohorts of VACTERL association, which have been reported in approximately 60–95% of affected individuals.<sup>7–30–33</sup> Additionally, vertebral anomalies are the most prevalent findings in the first-degree relatives of the probands in some cohorts,<sup>34–35</sup> thus highlighting the importance of vertebral anomalies as a major diagnostic feature for VACTERL association. In this review, we will summarise the genetic studies of the VACTERL association with an emphasis on vertebral anomalies.

## Vertebral anomalies

Vertebral anomalies in VACTERL association can be classified as (1) failure of formation, such as hemivertebrae, butterfly or wedge-shaped vertebrae; (2) failure of segmentation such as vertebral bars, fused vertebrae and block vertebrae; and (3) a combination of these two features, resulting in a mixed deformity.<sup>36–37</sup> Rib anomalies such

**Table 1** Monogenic diseases overlapping with VACTERL association

Syndrome	OMIM	Locus	Gene	Vertebral anomalies	Overlap malformations	Characteristic features beyond VACTERL association	Reference
Fanconi anaemia with VACTERL-H	227650; 300514	16q24; Xp22	<i>FANCA</i> ; <i>FANCB</i> , etc *	Same phenotype with VACTERL but lower frequency	V, A, C TE, R, L	Haematological anomalies; pigmentary changes; hydrocephalus	Holden <i>et al</i> <sup>13</sup>
Alagille syndrome	118450	20p12; 1p12-p11	<i>JAG1</i> ; <i>NOTCH2</i>	Mostly butterfly vertebra, occasionally hemivertebrae, fusion of vertebrae	V, C, R	Jaundice with conjugated hyperbilirubinemia; dysmorphic facies; posterior embryotoxon and retinal pigmentary changes	Turnpenny and Ellard <sup>14</sup>
Basal cell nevus syndrome	109400	9q22; 1p32; 10q24-q25	<i>PTCH1</i> ; <i>PTCH2</i> ; <i>SUFU</i>	Multiple fusion of vertebral bodies and ribs	V, L	Odontogenic keratocysts of the jaw; palmar or plantar pits; bilamellar calcification of the falx cerebri; basal cell tumours	Oostra and Maas; <sup>15</sup> Pino <i>et al</i> <sup>16</sup>
Baller–Gerold syndromes	218600	8q24	<i>RECQL4</i>	Rib fusion and flat vertebrae	V, A, C, R, L	Craniosynostosis; microcephaly	Murthy <i>et al</i> <sup>17</sup>
DiGeorge syndrome (22q11.2 deletion syndrome)	188400	22q11	<i>TBX1</i>	Hemivertebrae	V, C, R, L	Thymic abnormality; conotruncal cardiac anomaly; facial dysmorphism; hypocalcaemia	Tsirikos <i>et al</i> ; <sup>18</sup> Maggadottir and Sullivan <sup>19</sup>
Feingold syndrome	164280	2p23-24	<i>N-MYC</i>	Absence of the fifth sacral vertebra and fusion of C5–C7 in a case	V, C, TE, R, L	Microcephaly; brachymesophalangy	Celli <i>et al</i> <sup>20</sup>
McKusick–Kaufman syndrome	236700	20p12	<i>MKKS</i>	Vertebral anomalies in one case	V, C, L	Hydrometrocolpos; gastrointestinal malformations	Knowles <i>et al</i> <sup>21</sup>
CHARGE syndrome	214800	8q12	<i>CHD7</i>	Idiopathic scoliosis without vertebral anomalies	C, TE, R	Coloboma; choanal atresia/stenosis; hypoplasia/aplasia of semicircular, etc.	Hsu <i>et al</i> ; <sup>22</sup> Verloes <sup>23</sup>
Pallister–Hall syndrome	146510	7p14.1	<i>GLI3</i>	NA	A, C, R, L	Hypothalamic hamartoma; bifid epiglottis; craniofacial abnormalities	Demurger <i>et al</i> <sup>24</sup>
Townes–Brocks syndrome	107480	16q21.1	<i>SALL1</i>	NA	A, C, R, L	Dysplastic ears with hearing impairment; intellectual disability	Sudo <i>et al</i> <sup>25</sup>
Holt–Oram syndrome	142900	12q24	<i>TBX5</i>	NA	C, L	NA	Goldfarb and Wall <sup>26</sup>
Hemifacial microsomia (OAVS)	164210	14q32	NA	Hemivertebrae, fusion of vertebrae	V, C	Craniofacial anomalies; central nervous system defects: visual and hearing impairment	Beleza-Meireles <i>et al</i> <sup>27</sup>
TAR syndrome	274000	1q21	<i>RBM8A</i>	NA	C, R, L	Thrombocytopenia	Tassano <i>et al</i> <sup>28</sup>

\*Numbers of genes been implicated in the pathogenesis associated with Fanconi anaemia.<sup>29</sup> A, anal atresia; C, cardiac malformations; CHARGE, Coloboma, Heart anomaly, Atresia of choanae, Retardation of mental and somatic development, Genital hypoplasia, Ear abnormalities; L, limb abnormalities; NA, not available; OAVS, oculo-auriculo-vertebral spectrum; R, renal anomalies; TAR, thrombocytopenia-absent radius; TE, tracheo-oesophageal fistula; V, vertebral anomalies; VACTERL, vertebral anomalies (V), anal atresia (A), cardiac malformations (C), tracheo-oesophageal fistula (TE), renal dysplasia (R) and limb abnormalities (L); VACTERL-H, VACTERL association with hydrocephalus.

as rib fusion and increased or decreased number of ribs are commonly accompanied with vertebral anomalies. In some studies, rib anomalies may occur without vertebral anomalies.<sup>7 30 38 39</sup> Although patients with anorectal malformations may have dysplastic sacral vertebrae, it is not clear whether these should be regarded as a vertebral anomalies component for diagnosis of VACTERL syndrome.<sup>2</sup> Clinical signs of scoliosis or kyphosis may be the first sign of vertebral anomalies when VACTERL association is suspected.<sup>40</sup> Radiology is needed for discerning vertebral and rib anomalies.

As an example, we present a 2-year-old Chinese boy with VACTERL association. He was born with oesophageal atresia that was surgically corrected 4 days later. He had an uneventful infancy until his mother found him with a hump at lower waist a year later. Spinal X-ray and CT scan found a left hemivertebra between L3 and L4, and a right hemivertebra between L5 and S1 (figure 1), which caused evident lumbar scoliosis. He also had an extra thoracic vertebra and an extra pair of ribs without clinical symptoms. Abdominal ultrasound examination revealed horseshoe kidney without impairment of his renal function. He underwent resection of both hemivertebrae with internal fixation and recovered well postoperatively.

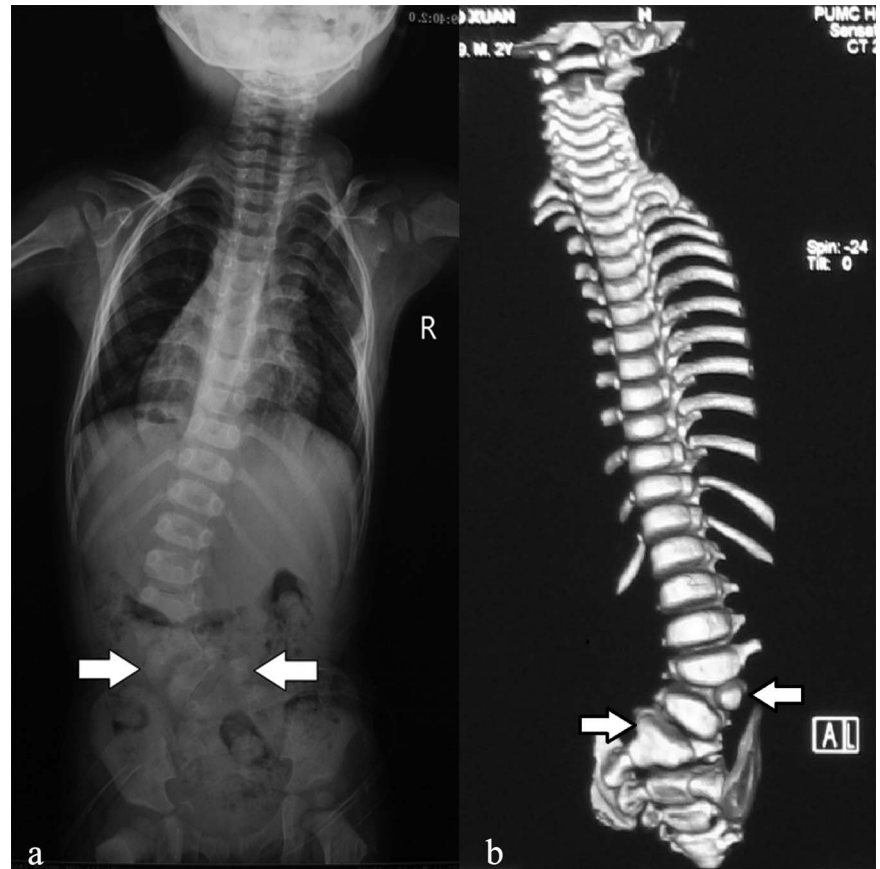## GENETIC STUDIES ON VACTERL ASSOCIATION

The aetiology of VACTERL association is not well understood (figure 2). As its phenotypes are too heterogeneous to be defined as a syndrome, and there is no major gene for this condition, thus it is still referred to as an ‘association’. The familial clustering phenomenon suggests a genetic role in its causality.<sup>34 41 42</sup>

## X-linked VACTERL association by *ZIC3* mutation

So far, the *ZIC3* gene has been demonstrated to cause X-linked VACTERL association. Different types of *ZIC3* mutations, including point mutations, deletions and polyalanine expansion, have been reported to be responsible for both VACTERL or VACTERL-like association.<sup>43–45</sup> Cardiac defects are most commonly found as *ZIC3* has important function in cardiac development and mutations in *ZIC3* also cause X-linked heterotaxy (MIM#306955);<sup>43 46 47</sup> anal atresia is present in most patients with *ZIC3* mutations; vertebral anomalies are not commonly observed and demonstrated phenotypic variability.<sup>45</sup> In animal models, *Zic3* knockout mice mimic the human heterotaxy and cardiac phenotype with occasional vertebral/rib anomalies. *Zic3* expression was present at all stages of embryonic

**Figure 1** Radiology of a 2-year-old boy diagnosed with VACTERL association. Preoperative spinal X-ray (A) and CT scan (B) revealed a left hemivertebra between L3 and L4, and a right hemivertebra between L5 and S1 that was fused with S1 vertebra (white arrows). R, right side of the body; VACTERL, vertebral anomalies (V), anal atresia (A), cardiac malformations (C), tracheo-oesophageal fistula (TE), renal dysplasia (R) and limb abnormalities (L).

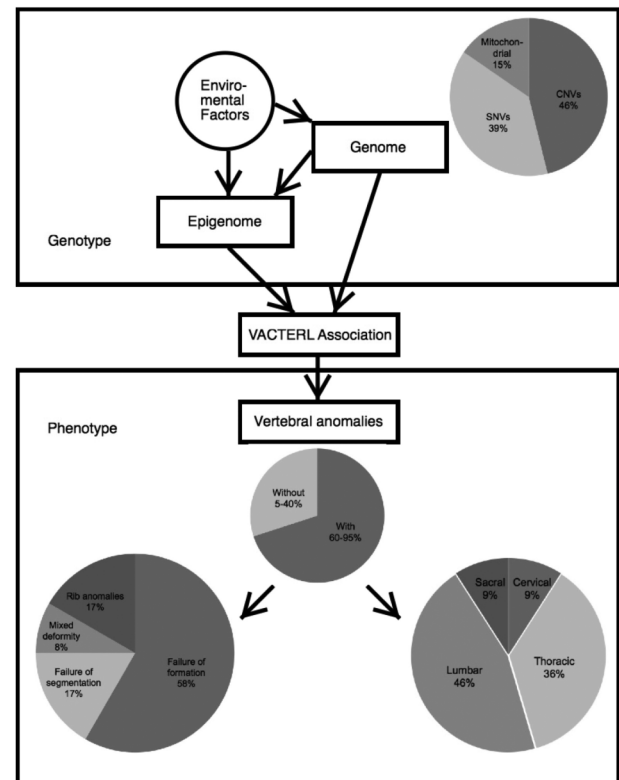


development within the anterior pre-somitic mesoderm but not in the developing anal region. Thus, anal atresia was not reported in *Zic3*-deficient mice,<sup>45</sup> which differs from humans where anal atresia is also prevalent with *ZIC3* mutations.

#### Sonic hedgehog pathway in VACTERL association

*SHH* gene has been implicated as the key inductive signal in patterning of the ventral neural tube, the anterior-posterior limb axis and the ventral somites.<sup>48</sup> Studies on animal models indicate that sonic hedgehog (Shh) pathway is important for VACTERL association. Kim *et al*<sup>49, 50</sup> identified the first animal model that recapitulated the human VACTERL syndrome by knocking out genes (*Shh* and *Gli*) in Shh pathway. With different genes of the Shh signalling pathway affected, the mutant mice display various combinations, ranges and severity of the VACTERL phenotypes, implying a dosage-dependent effect. Furthermore, a VACTERL-like phenotype was reported in murine with a novel hypomorphic mutation in the *Intraflagellar Transport Protein 172* (*Ift172*) gene.<sup>51</sup> The *Ift172* gene encodes a component of the intraflagellar transport, which appears to play an active role in Shh signalling, and Ift proteins are required for both Gli activator and Gli repressor function.<sup>52, 53</sup>

To the best of our knowledge, *SHH* or *GLI3* mutations have not been identified in VACTERL patients.<sup>54</sup> In humans, *SHH* mutation may cause more severe VACTERL phenotypes. Nowaczyk *et al*<sup>55</sup> reported a patient with holoprosencephaly 3 and *SHH* haploinsufficiency who suffered from sacral anomalies (cleft S1, hemivertebra at S2 and absence of the rest of the sacrum and coccyx), genitourinary abnormality, multiple segments of bowel atresia and limb anomalies. Although this patient has a distinctive diagnosis, the phenotypic features overlap with VACTERL association. There is a possibility that *SHH* mutation causes these overlapping phenotypes.



**Figure 2** General view of genetic findings and vertebral manifestations in VACTERL association. Mitochondrial, mitochondrial dysfunction; SNVs, single-nucleotide variants; VACTERL, vertebral anomalies (V), anal atresia (A), cardiac malformations (C), tracheo-oesophageal fistula (TE), renal dysplasia (R) and limb abnormalities (L).

Some genes that play roles in Shh pathway have been reported to be associated with VACTERL association. A heterozygous de novo 21bp deletion (c.163\_183del) in the exon 1 of the *HOXD13* gene,<sup>56</sup> a downstream target of *SHH*,<sup>57</sup> was identified in a 17-year-old girl, who was diagnosed with VACTERL association without vertebral anomalies. Another patient with rib anomalies diagnosed with VACTERL association was found with a 451 kb deletion at chromosome 3q28, which contains a single *LPP* gene.<sup>39</sup> This gene encodes LIM domain containing preferred translocation partner in lipoma that has been shown to bind PEA3, an ETS domain transcription factor that has a role in regulating the SHH pathway.<sup>58</sup> Moreover, CNV (micro-deletions) as well as point mutation in *FOXF1* gene have been identified in patients with VACTERL phenotypes.<sup>45 59</sup> In animal models, *Foxf1* has been found to be downregulated in *Shh*<sup>-/-</sup> mice<sup>60 61</sup> and the *Foxf1* heterozygotes have been shown to display tracheo-oesophageal atresia and fistulas.<sup>62 63</sup> Although *HOXD13*, *LPP* and *FOXF1* mutation were sporadic findings in individuals,<sup>64 65</sup> these studies argue in favour of that SHH pathway dysfunction is associated with VACTERL association.

### Candidate gene mutations and CNVs

Several candidate gene mutations and CNVs have been reported to be related to VACTERL association (summarised in table 2). So far, these candidate gene mutations and CNVs listed are found mostly in sporadic cases, which need further large sample verification or functional experiments to confirm their pathogenicity.

Although the genetic aetiology of VACTERL association has been far from established, previous studies did reveal some genetic mutations that can account for one or a few of the six CFs (table 2). For example, *DLL3* gene, which encodes a ligand for the Notch signalling pathway that coordinates somitogenesis,<sup>66</sup> has been found to cause block vertebrae in a Caucasian male VACTERL patient.<sup>67</sup> Saisawat *et al*<sup>68</sup> identified recessive mutations in the *TNF receptor-associated protein 1* (*TRAP1*) gene in three families with VACTERL association. They also proved that *Trap1* gene is highly expressed in the renal epithelia of 13.5-day-old mouse embryos and its mutations contribute to renal dysplasia.

Intriguingly, mutations of the same gene may cause variable expressivity among VACTERL patients, even within the same

**Table 2** Candidate genes and CNVs in VACTERL association

Chromosome region	Gene	Mutation	Function	Inheritance	Manifestations	Vertebral anomalies	Overlap syndrome	Reference
16p13.3	<i>TRAP1</i>	p.L253V and p.L525F*	Missense	Homozygous/compound heterozygous	V, A, C, TE, R	Hemivertebrae with rib anomalies	–	Saisawat <i>et al</i> <sup>68</sup>
9q21.13	<i>PCSK5</i>	p.C1624fs	Frameshift mutation	Heterozygous (inherited-fat)	V, C, R, L	Hemivertebrae	–	Nakamura <i>et al</i> <sup>71</sup>
16q24.1-q24.2	<i>FOXF1</i>	p.G220C	Missense/deletion	De novo	V, A, C, TE	Butterfly vertebrae	ACD/MPV	Stankiewicz <i>et al</i> <sup>59</sup> ; Hilger <i>et al</i> <sup>45</sup>
1q41	–	–	Duplication	De novo	V, A, C, TE, R	Butterfly vertebrae	–	Hilger <i>et al</i> <sup>73</sup>
8q24.3	–	–	Duplication	De novo	V, A, C, TE, R	Butterfly vertebrae	–	Hilger <i>et al</i> <sup>73</sup>
13q31.2-qter	–	–	Deletion	De novo	V, A, R, L	Butterfly vertebrae	–	Dworschak <i>et al</i> <sup>69</sup>
17p13.3	–	–	Deletion	NA	V, A, C, L	Butterfly vertebrae	Miller–Dieker syndrome	Ueda <i>et al</i> <sup>74</sup>
19q13.2	<i>DLL3</i>	p.G269A	Missense	Heterozygous (inherited-mat)	V, C, R, L	Block vertebrae	Spondylocostal dysostosis type I	Giampietro <i>et al</i> <sup>67</sup>
13q33.2-qter	–	–	Deletion	De novo	V, A	Block vertebrae	–	Dworschak <i>et al</i> <sup>69</sup>
22q11.2	–	–	Duplication	De novo	V, A, R	Fusion vertebrae (L4–L5)	22q11.2 duplication syndrome; DiGeorge syndrome	Schramm <i>et al</i> <sup>75</sup>
Y	–	–	Deletion in Yq and duplication in Yp	NA	V, A, R, L	Block and hemivertebrae in lumbar	–	Bhagat <sup>76</sup>
18q10-q11.2	–	–	Duplication	De novo	V, A, R, L	Dysplastic lumbar and sacral vertebrae, NO detail	–	Felix <i>et al</i> <sup>77</sup> ; van der Veken <i>et al</i> <sup>78</sup>
10q23.31	<i>PTEN</i>	p.H61D	Missense	De novo	V, C, TE, L	Rib anomalies (13 pairs of ribs)	Cowden syndrome	Reardon <i>et al</i> <sup>38</sup>
3q28	<i>LPP</i>	–	Deletion	De novo	V, C, TE, R	Rib anomalies	–	Arrington <i>et al</i> <sup>39</sup> ; Hernandez-Garcia <i>et al</i> <sup>65</sup>
5q11.2	–	–	Deletion	De novo	V, A, C	No detail	–	de Jonge <i>et al</i> <sup>79</sup>
19p13.3	–	–	Deletion	De novo/inherited-mat	V, A, C, TE, R, L	No detail	–	Peddibhotla <i>et al</i> <sup>72</sup>
2q31.1	<i>HOXD13</i>	–	Deletion	De novo	A, C, L	Not reported	Brachydactyly-syndactyly syndrome	Garcia-Barcelo <i>et al</i> <sup>66</sup>
10q24.32	<i>FGF8</i>	p.G29_R34dup; p.P26L	In-frame duplication; missense	Heterozygous	A, C, TE, R, L	Not reported	Kallmann syndrome	Zeidler <i>et al</i> <sup>80</sup>

\*Four cases of *TRAP1* mutations have been reported and the only case with vertebral anomalies is listed.

A, anal atresia; ACD/MPV, alveolar capillary dysplasia with misalignment of pulmonary veins; C, cardiac malformations; L, limb abnormalities; NA, not available; R, renal anomalies; TE, tracheo-oesophageal fistula; V, vertebral anomalies; VACTERL, vertebral anomalies (V), anal atresia (A), cardiac malformations (C), tracheo-oesophageal fistula (TE), renal dysplasia (R) and limb abnormalities (L).



family. Dworschak *et al*<sup>69</sup> identified chromosome 13q deletions in two patients with VACTERL phenotypes. The girl was born with perineal fistula, renal hypoplasia, bilateral triphalangeal thumbs and oligodactyly, butterfly vertebrae and cerebral anomalies, and died at 10 months of age. The second patient, a male child, suffered from perineal fistula, block vertebrae at C2–C3 and C4–C5–C6 and bilateral hearing loss. *Pcsk5* gene has been identified as a candidate gene of VACTERL association in mice.<sup>70</sup> Nakamura *et al*<sup>71</sup> reported a Japanese VACTERL boy with eighth thoracic hemivertebra having a frameshift mutation of *PCSK5*, while his healthy father also shared the same mutation. Peddibhotla *et al*<sup>72</sup> reported eight patients with chromosome 19p13.3 microdeletions and six of them fulfilled the diagnostic criteria for VACTERL association. Among the six VACTERL patients, one patient has vertebral anomalies while her two children, although with VACTERL association, are free from vertebral anomalies. These phenomena imply other modification factors desperate for further investigation in this condition.

### Chromosomal aberrations

Chromosomal aberrations also contribute to VACTERL associations. Several case reports have been published that describe chromosomal anomalies in VACTERL patients as Felix *et al*<sup>77</sup> and Brosens *et al*<sup>81</sup> reviewed previously. However, chromosomal aberrations are not included here as they also contribute to the occurrence of congenital malformations beyond what is typically observed in VACTERL association.

### Mitochondrial dysfunction

Damian *et al*<sup>82</sup> first reported an A to G transversion in the mitochondrial NP3243 mutation in cystic kidney of a VACTERL child. Spinal radiograph showed multiple cervical and thoracic vertebral wedging, fusion and fission. She also had limb abnormalities, cardiac malformations and renal anomalies. This child belonged to a family in which other members had mitochondrial encephalomyopathy, lactic acidosis, and stroke-like episodes syndrome and chronic progressive external ophthalmoplegia, which suggests mitochondrial dysfunction may contribute to VACTERL syndrome.<sup>83</sup> Stone *et al*<sup>84</sup> studied a cohort of 62 patients with VACTERL association and none of the affected children had measurable levels of the NP 3243 mutation. A few authors have previously reported an association of VACTERL association in patients with mitochondrial disorders known as complex IV respiratory chain deficiency.<sup>85–87</sup> Overall, four of the five individuals presented with vertebral anomalies; three showed oesophageal involvement; two had anal atresia and two patients presented with additional minor dysmorphic features. Different combinations of other multiple congenital malformations have also been reported in a series of children with respiratory chain deficiency, leading to the hypothesis that in these patients congenital anomalies might result from an abnormal development during embryogenesis through either a lack of ATP or an alteration of apoptosis controlled by the mitochondrial machinery. However, it is also possible that mitochondrial dysfunction and congenital malformations in the patient described here are both secondary to an as yet unidentified process.<sup>88</sup> In conclusion, whether mutation of mitochondrial dysfunction causes VACTERL association is still controversial. Some clinical signs and symptoms that may be not common in patients with VACTERL association, including progressive muscle weakness, characteristic patterns of cardiac, neurological and exocrine dysfunction,<sup>89</sup> may suggest a potential existence of mitochondrial dysfunction.

In summary, the aetiology of VACTERL association appears to be heterogeneous, suggesting that it may be a complex condition.

Besides the gene mutations and CNVs mentioned above, some other factors such as intronic mutations or epigenetic factors may also play important roles in this condition. Environmental factors including maternal diabetes<sup>90</sup> and exposure to statins,<sup>91</sup> which may associated with congenital anomalies, may play a significant role in the pathogenesis of VACTERL syndrome.

### CONCLUSION

VACTERL association is a rare and complex condition with highly heterogeneous aetiology and manifestations. At the present time, there appears to be evidence for genetic factors contributing to VACTERL syndrome including single-gene mutations, CNVs and structure variants to mitochondrial dysfunction. Future studies are needed to identify epigenetics and environmental causes for VACTERL syndrome. Targeted genetic testing can contribute to eliminating overlapping diagnoses from further consideration in an affected individual. Notably, a given variant may explain a particular CF of VACTERL association, so it may be worth trying to investigate this sophisticated association by focusing on one of the six component features. ‘Vertebral anomalies’ is one of the core component features of VACTERL association, including formation and segmentation vertebral. Wu *et al*<sup>92</sup> recently described a compound heterozygous model in which a null allele mutation in combination with a common haplotype of *TBX6* causes congenital scoliosis, suggesting that genetic factors play an important role in vertebral anomalies. Additionally, we suggest that the genetic mutations may contribute to vertebral anomalies in a certain syndrome. Alternatively, VACTERL association may be caused by a ‘two-hit’ model in which two genes or one gene in combination with an epigenetic factor may elicit all associated features.<sup>93</sup> In the future, combination of new genomic technologies such as whole-exome sequencing, whole-genome sequencing, comparative genomic hybridisation array and whole-genome bisulfite sequencing may well reveal a surprising number of additional contributing loci, delineating the entire spectrum of the VACTERL association in humans.

### Author affiliations

<sup>1</sup>Department of Orthopedic Surgery, Peking Union Medical College Hospital, Peking Union Medical College and Chinese Academy of Medical Sciences, Beijing, China  
<sup>2</sup>Beijing Key Laboratory for Genetic Research of Skeletal Deformity, Beijing, China  
<sup>3</sup>Department of Pediatrics, University of Wisconsin School of Medicine and Public Health, Madison, Wisconsin, USA  
<sup>4</sup>Department of Central Laboratory, Peking Union Medical College Hospital, Peking Union Medical College and Chinese Academy of Medical Sciences, Beijing, China

**Acknowledgements** The authors thank Dr Pengfei Liu from the Department of Molecular and Human Genetics, Baylor College of Medicine, and Dr Xiaoyue Wang from the State Key Laboratory of Medical Molecular Biology, Chinese Academy of Medical Sciences, for their comments on the manuscript. They also express gratitude to the patient described in this article for his willingness to take part in this study.

**Contributors** YC, ZL and JC contributed equally to this article. YC, NW and ZW conceived and designed the review. YC interpreted data and contributed to the manuscript preparation. ZL and JC drafted the main manuscript. NW, ZW, YZ, GQ and PFG critically revised the manuscript and made comments on the structure, details and grammar for the article. SL, WC and GL contributed to data acquisition. All authors approved the final manuscript.

**Funding** The research was supported by National Natural Sciences Foundation of China (81501852, 81472046, 81271942, 81130034, 81472045), Distinguished Young Scholars of Peking Union Medical College Hospital (JQ201506), Beijing nova program (2016) and The Central Level Public Interest Program for Science Research Institute (No 13, 2015).

**Competing interests** None declared.

**Ethics approval** Ethics Committee of Peking Union Medical College Hospital.

**Provenance and peer review** Commissioned; externally peer reviewed.

**Open Access** This is an Open Access article distributed in accordance with the Creative Commons Attribution Non Commercial (CC BY-NC 4.0) license, which

permits others to distribute, remix, adapt, build upon this work non-commercially, and license their derivative works on different terms, provided the original work is properly cited and the use is non-commercial. See: <http://creativecommons.org/licenses/by-nc/4.0/>

## REFERENCES

- 1 Temtamy SA, Miller JD. Extending the scope of the VATER association: definition of the VATER syndrome. *J Pediatr* 1974;85:345–9.
- 2 Solomon BD. VACTERL/VATER Association. *Orphanet J Rare Dis* 2011;6:56.
- 3 Quan L, Smith DW. The VATER association. Vertebral defects, Anal atresia, T-E fistula with esophageal atresia, Radial and Renal dysplasia: a spectrum of associated defects. *J Pediatr* 1973;82:104–7.
- 4 Khoury MJ, Cordero JF, Greenberg F, James LM, Erickson JD. A population study of the VACTERL association: evidence for its etiologic heterogeneity. *Pediatrics* 1983;71:815–20.
- 5 Botto LD, Khoury MJ, Mastroiacovo P, Castilla EE, Moore CA, Skjaerven R, Mutchinick OM, Borman B, Cocchi G, Czeisel AE, Goujard J, Irgens LM, Lancaster PA, Martinez-Frias ML, Merlob P, Ruusinen A, Stoll C, Sumiyoshi Y. The spectrum of congenital anomalies of the VATER association: an international study. *Am J Med Genet A* 1997;71:8–15.
- 6 Källén K, Mastroiacovo P, Castilla EE, Robert E, Källén B. VATER non-random association of congenital malformations: study based on data from four malformation registers. *Am J Med Genet* 2001;101:26–32.
- 7 Solomon BD, Pineda-Alvarez DE, Raam MS, Bous SM, Keaton AA, Velez JL, Cummings DA. Analysis of component findings in 79 patients diagnosed with VACTERL association. *Am J Med Genet A* 2010;152A:2236–44.
- 8 Solomon BD, Bear KA, Kimonis V, de Klein A, Scott DA, Shaw-Smith C, Tibboel D, Reutter H, Giampietro PF. Clinical geneticists' views of VACTERL/VATER association. *Am J Med Genet A* 2012;158A:3087–100.
- 9 Giampietro PF, Adler-Brecher B, Verlander PC, Pavlakis SG, Davis JG, Auerbach AD. The need for more accurate and timely diagnosis in Fanconi anemia: a report from the International Fanconi Anemia Registry. *Pediatrics* 1993;91:1116–20.
- 10 Faivre L, Portnoi MF, Pals G, Stoppa-Lyonnet D, Le Merrer M, Thauvin-Robinet C, Huet F, Mathew CG, Joenje H, Verloes A, Baumann C. Should chromosome breakage studies be performed in patients with VACTERL association? *Am J Med Genet A* 2005;137:55–8.
- 11 Alter BP, Rosenberg PS. VACTERL-H Association and Fanconi Anemia. *Mol Syndromol* 2013;4:87–93.
- 12 Winberg J, Gustavsson P, Papadogiannakis N, Sahlin E, Bradley F, Nordenskjöld E, Svensson PJ, Anneren G, Iwarsson E, Nordgren A, Nordenskjöld A. Mutation screening and array comparative genomic hybridization using a 180K oligonucleotide array in VACTERL association. *PLoS ONE* 2014;9:e85313.
- 13 Holden ST, Cox JJ, Kesterton I, Thomas NS, Carr C, Woods CG. Fanconi anaemia complementation group B presenting as X linked VACTERL with hydrocephalus syndrome. *J Med Genet* 2006;43:750–4.
- 14 Turnpenny PD, Ellard S. Alagille syndrome: pathogenesis, diagnosis and management. *Eur J Hum Genet* 2012;20:251–7.
- 15 Oostra RJ, Maas M. Bifid ribs and unusual vertebral anomalies diagnosed in an anatomical specimen. Gorlin syndrome? *Am J Med Genet A* 2006;140:2135–8.
- 16 Pino LC, Balassiano LK, Sessim M, de Almeida AP, Empinotti VD, Semenovich I, Treu C, Lupi O. Basal cell nevus syndrome: clinical and molecular review and case report. *Int J Dermatol* 2016;55:367–75.
- 17 Murthy J, Babu R, Ramanan PV. Radial, renal and craniofacial anomalies: Baller-Gerold syndrome. *Indian J Plast Surg* 2008;41:76–8.
- 18 Tsirikos AI, Khan LA, McMaster MJ. Spinal deformity in patients with DiGeorge syndrome. *J Spinal Disord Tech* 2010;23:208–14.
- 19 Maggadottir SM, Sullivan KE. The diverse clinical features of chromosome 22q11.2 deletion syndrome (DiGeorge syndrome). *J Allergy Clin Immunol Pract* 2013;1:589–94.
- 20 Celli J, van Bokhoven H, Brunner HG. Feingold syndrome: clinical review and genetic mapping. *Am J Med Genet A* 2003;122A:294–300.
- 21 Knowles JC, Brandt IK, Bull MJ. Kaufman syndrome (hydrometrocolpos, polydactyly, and congenital heart disease) with pituitary dysplasia, choanal atresia, and vertebral anomalies. *Am J Med Genet* 1981;8:389–93.
- 22 Hsu P, Ma A, Wilson M, Williams G, Curotta J, Munns CF, Mehr S. CHARGE syndrome: a review. *J Paediatr Child Health* 2014;50:504–11.
- 23 Verloes A. Updated diagnostic criteria for CHARGE syndrome: a proposal. *Am J Med Genet A* 2005;133A:306–8.
- 24 Demurger F, Ichkour A, Mougou-Zerelli S, Le Merrer M, Goudefroye G, Delezoide AL, Quélin C, Manouvrier S, Baujat G, Fradin M, Pasquier L, Megarbané A, Faivre L, Baumann C, Nampoothiri S, Roume J, Isidor B, Lacombe D, Delrue MA, Mercier S, Philip N, Schaefer E, Holder M, Krause A, Laffargue F, Sinico M, Amram D, Andre G, Liqueur A, Rossi M, Amiel J, Giuliano F, Boule O, Dieux-Coeslier A, Jacquemont ML, Afenjar A, Van Maldergem L, Lackmy-Port-Lis M, Vincent-Delorme C, Chauvet ML, Cormier-Daire V, Devisme L, Geneviève D, Munnich A, Viot G, Raoul O, Romana S, Gonzales M, Encha-Razavi F, Odent S, Vekemans M, Attie-Bitach T. New insights into genotype-phenotype correlation for GLI3 mutations. *Eur J Hum Genet* 2015;23:92–102.
- 25 Sudo Y, Numakura C, Abe A, Aiba S, Matsunaga A, Hayasaka K. Phenotypic variability in a family with Townes-Brocks syndrome. *J Hum Genet* 2010;55:550–1.
- 26 Goldfarb CA, Wall LB. Holt-Oram syndrome. *J Hand Surg Am* 2014;39:1646–8.
- 27 Belez-Meireles A, Hart R, Clayton-Smith J, Oliveira R, Reis CF, Venâncio M, Ramos F, Sá J, Ramos L, Cunha E, Pires LM, Carreira IM, Scholey R, Wright R, Urquhart JE, Briggs TA, Kerr B, Kingston H, Metcalfe K, Donnai D, Newman WG, Saraiva JM, Tassabehji M. Oculo-auriculo-vertebral spectrum: clinical and molecular analysis of 51 patients. *Eur J Med Genet* 2015;58:455–65.
- 28 Tassano E, Gimelli S, Divizia MT, Lerone M, Vaccari C, Puliti A, Gimelli G. Thrombocytopenia-absent radius (TAR) syndrome due to compound inheritance for a 1q21.1 microdeletion and a low-frequency noncoding RBM8A SNP: a new familial case. *Mol Cytogenet* 2015;8:87.
- 29 Dong H, Nebert DW, Bruford EA, Thompson DC, Joenje H, Vasilou V. Update of the human and mouse Fanconi anemia genes. *Hum Genomics* 2015;9:32.
- 30 Rittler M, Paz JE, Castilla EE. VACTERL association, epidemiologic definition and delineation. *Am J Med Genet* 1996;63:529–36.
- 31 Oral A, Caner I, Yigit M, Kantarci M, Olgun H, Ceviz N, Salman AB. Clinical characteristics of neonates with VACTERL association. *Pediatr Int* 2012;54:361–4.
- 32 Salinas-Torres VM, Pérez-García N, Pérez-García G. Clinical, cytogenetic, environmental and inheritance findings in Mexican neonates with VACTERL association. *Indian J Pediatr* 2015;82:84–8.
- 33 Solomon BD, Baker LA, Bear KA, Cunningham BK, Giampietro PF, Hadigan C, Hadley DW, Harrison S, Levitt MA, Niforatos N, Paul SM, Raggio C, Reutter H, Warren-Mora N. An approach to the identification of anomalies and etiologies in neonates with identified or suspected VACTERL (vertebral defects, anal atresia, tracheo-esophageal fistula with esophageal atresia, cardiac anomalies, renal anomalies, and limb anomalies) association. *J Pediatr* 2014;164:451–7.e1.
- 34 Solomon BD, Pineda-Alvarez DE, Raam MS, Cummings DA. Evidence for inheritance in patients with VACTERL association. *Hum Genet* 2010;127:731–3.
- 35 Hilger A, Schramm C, Draaken M, Mughal SS, Dworschak G, Bartels E, Hoffmann P, Nöthen MM, Reutter H, Ludwig M. Familial occurrence of the VATER/VACTERL association. *Pediatr Surg Int* 2012;28:725–9.
- 36 Offiah A, Alman B, Cornier AS, Giampietro PF, Tassy O, Wade A, Turnpenny PD. Pilot assessment of a radiologic classification system for segmentation defects of the vertebrae. *Am J Med Genet A* 2010;152A:1357–71.
- 37 Giampietro PF, Raggio CL, Blank RD, McCarty C, Broeckel U, Pickart MA. Clinical, genetic and environmental factors associated with congenital vertebral malformations. *Mol Syndromol* 2013;4:94–105.
- 38 Reardon W, Zhou XP, Eng C. A novel germline mutation of the PTEN gene in a patient with macrocephaly, ventricular dilatation, and features of VATER association. *J Med Genet* 2001;38:820–3.
- 39 Arrington CB, Patel A, Bacino CA, Bowles NE. Haploinsufficiency of the LIM domain containing preferred translocation partner in lipoma (LPP) gene in patients with tetralogy of Fallot and VACTERL association. *Am J Med Genet A* 2010;152A:2919–23.
- 40 Raam MS, Pineda-Alvarez DE, Hadley DW, Solomon BD. Long-term outcomes of adults with features of VACTERL association. *Eur J Med Genet* 2011;54:34–41.
- 41 Brown AK, Roddam AW, Spitz L, Ward SJ. Oesophageal atresia, related malformations, and medical problems: a family study. *Am J Med Genet A* 1999;85:31–7.
- 42 van Rooij IA, Wijers CH, Rieu PN, Hendriks HS, Brouwers MM, Knoers NV, de Blaauw I, Roeleveld N. Maternal and paternal risk factors for anorectal malformations: a Dutch case-control study. *Birth Defects Res Part A Clin Mol Teratol* 2010;88:152–8.
- 43 Wessels MW, Kuchinka B, Heydanus R, Smit BJ, Dooijes D, de Krijger RR, Lequin MH, de Jong EM, Husen M, Willems PJ, Casey B. Polyalanine expansion in the ZIC3 gene leading to X-linked heterotaxy with VACTERL association: a new polyalanine disorder? *J Med Genet* 2010;47:351–5.
- 44 Chung B, Shaffer LG, Keating S, Johnson J, Casey B, Chitayat D. From VACTERL-H to heterotaxy: variable expressivity of ZIC3-related disorders. *Am J Med Genet A* 2011;155A:1123–8.
- 45 Hilger AC, Halbritter J, Pennimpede T, van der Ven A, Sarma G, Braun DA, Porath JD, Kohl S, Hwang DY, Dworschak GC, Hermann BG, Pavlova A, El-Maarri O, Nöthen MM, Ludwig M, Reutter H, Hildebrandt F. Targeted Re-Sequencing of 29 Candidate Genes and Mouse Expression Studies Implicate ZIC3 and FOXF1 in Human VATER/VATER Association. *Hum Mutat* 2015;36:1150–4.
- 46 Ware SM, Peng J, Zhu L, Fernbach S, Colicos S, Casey B, Towbin J, Belmont JW. Identification and functional analysis of ZIC3 mutations in heterotaxy and related congenital heart defects. *Am J Hum Genet* 2004;74:93–105.
- 47 Cowan J, Tariq M, Ware SM. Genetic and functional analyses of ZIC3 variants in congenital heart disease. *Hum Mutat* 2014;35:66–75.
- 48 Endo T. Molecular mechanisms of skeletal muscle development, regeneration, and osteogenic conversion. *Bone* 2015;80:2–13.
- 49 Kim PC, Mo R, Hui CC. Murine models of VACTERL syndrome: Role of sonic hedgehog signaling pathway. *J Pediatr Surg* 2001;36:381–4.
- 50 Kim J, Kim P, Hui CC. The VACTERL association: lessons from the Sonic hedgehog pathway. *Clin Genet* 2001;59:306–15.
- 51 Friedland-Little JM, Hoffmann AD, Ocbina PJ, Peterson MA, Bosman JD, Chen Y, Cheng SY, Anderson KV, Moskowitz IP. A novel murine allele of Intraflagellar Transport Protein 172 causes a syndrome including VACTERL-like features with hydrocephalus. *Hum Mol Genet* 2011;20:3725–37.

- 52 Haycraft CJ, Banizs B, Aydin-Son Y, Zhang Q, Michaud EJ, Yoder BK. Gli2 and Gli3 localize to cilia and require the intraflagellar transport protein polaris for processing and function. *PLoS Genet* 2005;1:e53.
- 53 Ocbina PJ, Anderson KV. Intraflagellar transport, cilia, and mammalian Hedgehog signaling: analysis in mouse embryonic fibroblasts. *Dev Dyn* 2008;237:2030–8.
- 54 Aguinaga M, Zenteno JC, Pérez-Cano H, Morán V. Sonic hedgehog mutation analysis in patients with VACTERL association. *Am J Med Genet A* 2010;152A:781–3.
- 55 Nowaczyk MJ, Huggins MJ, Tomkins DJ, Rossi E, Ramsay JA, Woulfe J, Scherer SW, Belloni E. Holoprosencephaly, sacral anomalies, and situs ambiguus in an infant with partial monosomy 7q/trisomy 2p and SHH and HLXB9 haploinsufficiency. *Clin Genet* 2000;57:388–93.
- 56 Garcia-Barceló MM, Wong KK, Lui VC, Yuan ZW, So MT, Ngan ES, Miao XP, Chung PH, Khong PL, Tam PK. Identification of a HOXD13 mutation in a VACTERL patient. *Am J Med Genet A* 2008;146a:3181–5.
- 57 Tarchini B, Duboule D, Kmita M. Regulatory constraints in the evolution of the tetrapod limb anterior-posterior polarity. *Nature* 2006;443:985–8.
- 58 Guo B, Sallis RE, Greenall A, Petit MM, Jansen E, Young L, Van de Ven WJ, Sharrock AD. The LIM domain protein LPP is a coactivator for the ETS domain transcription factor PEA3. *Mol Cell Biol* 2006;26:4529–38.
- 59 Stankiewicz P, Sen P, Bhatt SS, Storer M, Xia Z, Bejjani BA, Ou Z, Wisniewska J, Driscoll DJ, Maisenbacher MK, Bolivar J, Bauer M, Zackai EH, McDonald-McGinn D, Nowaczyk MM, Murray M, Huested V, Mascotti K, Schultz R, Hallam L, McRae D, Nicholson AG, Newbury R, Durham-O'Donnell J, Knight G, Kini U, Shaikh TH, Martin V, Tyreman M, Simonic I, Willatt L, Paterson J, Mehta S, Rajan D, Fitzgerald T, Gribble S, Prigmore E, Patel A, Shaffer LG, Carter NP, Cheung SW, Langston C, Shaw-Smith C. Genomic and gene deletions of the FOX gene cluster on 16q24.1 and inactivating mutations of FOXF1 cause alveolar capillary dysplasia and other malformations. *Am J Hum Genet* 2009;84:780–91.
- 60 Astorga J, Carlsson P. Hedgehog induction of murine vasculogenesis is mediated by Foxf1 and Bmp4. *Development* 2007;134:3753–61.
- 61 Madison BB, McKenna LB, Dolson D, Epstein DJ, Kaestner KH. FoxF1 and FoxL1 link hedgehog signaling and the control of epithelial proliferation in the developing stomach and intestine. *J Biol Chem* 2009;284:5936–44.
- 62 Mahlapuu M, Enerbäck S, Carlsson P. Haploinsufficiency of the forkhead gene Foxf1, a target for sonic hedgehog signaling, causes lung and foregut malformations. *Development* 2001;128:2397–406.
- 63 Shaw-Smith C. Genetic factors in esophageal atresia, tracheo-esophageal fistula and the VACTERL association: roles for FOXF1 and the 16q24.1 FOX transcription factor gene cluster, and review of the literature. *Eur J Med Genet* 2010;53:6–13.
- 64 Agochukwu NB, Pineda-Alvarez DE, Keaton AA, Warren-Mora N, Raam MS, Kamat A, Chandrasekharappa SC, Solomon BD. Analysis of FOXF1 and the FOX gene cluster in patients with VACTERL association. *Eur J Med Genet* 2011;54:323–8.
- 65 Hernández-García A, Brosens E, Zaveri HP, de Jong EM, Yu Z, Namwanje M, Mayle A, Fernandes CJ, Lee B, Blazo M, Lalani SR, Tibboel D, de Klein A, Scott DA. Contribution of LPP copy number and sequence changes to esophageal atresia, tracheoesophageal fistula, and VACTERL association. *Am J Med Genet A* 2012;158A:1785–7.
- 66 Turnpenny PD, Whittock N, Duncan J, Dunwoodie S, Kusumi K, Ellard S. Novel mutations in DLL3, a somitogenesis gene encoding a ligand for the Notch signalling pathway, cause a consistent pattern of abnormal vertebral segmentation in spondylocostal dysostosis. *J Med Genet* 2003;40:333–9.
- 67 Giampietro PF, RagGIO CL, Reynolds C, Ghebranious N, Burmester JK, Glurich I, Rasmussen K, McPherson E, Pauli RM, Shukla SK, Merchant S, Jacobsen FS, Faciszewski T, Blank RD. DLL3 as a candidate gene for vertebral malformations. *Am J Med Genet A* 2006;140:2447–53.
- 68 Saisawat P, Kohl S, Hilger AC, Hwang DY, Yung Gee H, Dworschak GC, Tasic V, Pennimpede T, Natarajan S, Sperry E, Matassa DS, Stajic N, Bogdanovic R, de Blaauw I, Marcellis CL, Wijers CH, Bartels E, Schmiedeke E, Schmidt D, Märzheuser S, Grasshoff-Derr S, Holland-Cunz S, Ludwig M, Nothen MM, Draaken M, Brosens E, Heij H, Tibboel D, Hermann BG, Solomon BD, de Klein A, van Rooij IA, Esposito F, Reutter HM, Hildebrandt F. Whole-exome resequencing reveals recessive mutations in TRAP1 in individuals with CAKUT and VACTERL association. *Kidney Int* 2014;85:1310–17.
- 69 Dworschak GC, Draaken M, Marcellis C, de Blaauw I, Pfundt R, van Rooij IA, Bartels E, Hilger A, Jenetzky E, Schmiedeke E, Grasshoff-Derr S, Schmidt D, Märzheuser S, Hosie S, Weih S, Holland-Cunz S, Palta M, Leonhardt J, Schäfer M, Kujath C, Rissmann A, Nöthen MM, Zwink N, Ludwig M, Reutter H. De novo 13q deletions in two patients with mild anorectal malformations as part of VATER/VACTERL and VATER/VACTERL-like association and analysis of EFN2 in patients with anorectal malformations. *Am J Med Genet A* 2013;161A:3035–41.
- 70 Szumska D, Pielas G, Essalmani R, Bilski M, Mesnard D, Kaur K, Franklyn A, El Omari K, Jefferis J, Benthall J, Taylor JM, Schneider JE, Arnold SJ, Johnson P, Tymowska-Lalanne Z, Stammers D, Clarke K, Neubauer S, Morris A, Brown SD, Shaw-Smith C, Cama A, Capra V, Ragoussis J, Constam D, Seidah NG, Prat A, Bhattacharya S. VACTERL/caudal regression/Currarino syndrome-like malformations in mice with mutation in the proprotein convertase Pcsk5. *Genes Dev* 2008;22:1465–77.
- 71 Nakamura Y, Kikugawa S, Seki S, Takahata M, Iwasaki N, Terai H, Matsubara M, Fujioka F, Inagaki H, Kobayashi T, Kimura T, Kurahashi H, Kato H. PCSK5 mutation in a patient with the VACTERL association. *BMC Res Notes* 2015;8:228.
- 72 Peddibhotla S, Khalifa M, Probst FJ, Stein J, Harris LL, Kearney DL, Vance GH, Bull MJ, Grange DK, Schärer GH, Kang SH, Stankiewicz P, Bacino CA, Cheung SW, Patel A. Expanding the genotype-phenotype correlation in telomeric 19p13.3 microdeletions using high resolution clinical chromosomal microarray analysis. *Am J Med Genet A* 2013;161A:2953–63.
- 73 Hilger A, Schramm C, Pennimpede T, Wittler L, Dworschak GC, Bartels E, Engels H, Zink AM, Degenhardt F, Müller AM, Schmiedeke E, Grasshoff-Derr S, Märzheuser S, Hosie S, Holland-Cunz S, Wijers CH, Marcellis CL, van Rooij IA, Hildebrandt F, Hermann BG, Nöthen MM, Ludwig M, Reutter H, Draaken M. De novo microduplications at 1q41, 2q37.3, and 8q24.3 in patients with VATER/VACTERL association. *Eur J Hum Genet* 2013;21:1377–82.
- 74 Ueda H, Sugiyama T, Takeshita S, Ito K, Kakita H, Nagasaki R, Kurosawa K, Saitoh S. Combination of Miller-Dieker syndrome and VACTERL association causes extremely severe clinical presentation. *Eur J Pediatr* 2014;173:1541–4.
- 75 Schramm C, Draaken M, Bartels E, Boemers TM, Aretz S, Brockschmidt FF, Nöthen MM, Ludwig M, Reutter H. De novo microduplication at 22q11.21 in a patient with VACTERL association. *Eur J Med Genet* 2011;54:9–13.
- 76 Bhagat M. VACTERL association-type anomalies in a Male neonate with a Y-chromosome abnormality. *Oxf Med Case Reports* 2015;2015:164–6.
- 77 Felix JF, Tibboel D, de Klein A. Chromosomal anomalies in the aetiology of oesophageal atresia and tracheo-oesophageal fistula. *Eur J Med Genet* 2007;50:163–75.
- 78 van der Veken LT, Dieleman MM, Douben H, van de Brug JC, van de Graaf R, Hooijboom AJ, Poddighe PJ, de Klein A. Low grade mosaic for a complex supernumerary ring chromosome 18 in an adult patient with multiple congenital anomalies. *Mol Cytogenet* 2010;3:13.
- 79 de Jong EM, Douben H, Eussen H, Felix JF, Wessels MW, Poddighe PJ, Nikkels PG, de Krijger RR, Tibboel D, de Klein A. 5q11.2 deletion in a patient with tracheal agenesis. *Eur J Hum Genet* 2010;18:1265–8.
- 80 Zeidler C, Woelfle J, Draaken M, Mughal SS, Große G, Hilger AC, Dworschak GC, Boemers TM, Jenetzky E, Zwink N, Lacher M, Schmidt D, Schmiedeke E, Grasshoff-Derr S, Märzheuser S, Holland-Cunz S, Schäfer M, Bartels E, Keppler K, Palta M, Leonhardt J, Kujath C, Rissmann A, Nöthen MM, Reutter H, Ludwig M. Heterozygous FGFR3 mutations in patients presenting cryptorchidism and multiple VATER/VACTERL features without limb anomalies. *Birth Defects Res Part A Clin Mol Teratol* 2014;100:750–9.
- 81 Brosens E, Eussen H, van Bever Y, van der Helm RM, Ijsseltijn H, Zaveri HP, Wijnen R, Scott DA, Tibboel D, de Klein A. VACTERL Association Etiology: The Impact of de novo and Rare Copy Number Variations. *Mol Syndromol* 2013;4:20–6.
- 82 Damian MS, Seibel P, Schachenmayr W, Reichmann H, Dorndorf W. VACTERL with the mitochondrial np 3243 point mutation. *Am J Med Genet* 1996;62:398–403.
- 83 Pavlakis SG, Phillips PC, DiMauro S, De Vivo DC, Rowland LP. Mitochondrial myopathy, encephalopathy, lactic acidosis, and stroke-like episodes: a distinctive clinical syndrome. *Ann Neurol* 1984;16:481–8.
- 84 Stone DL, Biesecker LG. Mitochondrial NP 3243 point mutation is not a common cause of VACTERL association. *Am J Med Genet* 1997;72:237–8.
- 85 Cormier-Daire V, Rustin P, Rötig A, Chrétien D, Le Merrer M, Belli D, Le Goff A, Hubert P, Ricour C, Munnich A. Craniofacial anomalies and malformations in respiratory chain deficiency. *Am J Med Genet* 1996;66:457–63.
- 86 von Kleist-Retzow JC, Cormier-Daire V, Viot G, Goldenberg A, Mardach B, Amiel J, Saada P, Dumez Y, Brunelle F, Saudubray JM, Chrétien D, Rötig A, Rustin P, Munnich A, De Lonlay P. Antenatal manifestations of mitochondrial respiratory chain deficiency. *J Pediatr* 2003;143:208–12.
- 87 Thauvin-Robinet C, Faivre L, Huet F, Journeau P, Glorion C, Rustin P, Rötig A, Munnich A, Cormier-Daire V. Another observation with VATER association and a complex IV respiratory chain deficiency. *Eur J Med Genet* 2006;49:71–7.
- 88 Solomon BD, Patel A, Cheung SW, Pineda-Alvarez DE. VACTERL association and mitochondrial dysfunction. *Birth Defects Res Part A Clin Mol Teratol* 2011;91:192–4.
- 89 Siebel S, Solomon BD. Mitochondrial Factors and VACTERL Association-Related Congenital Malformations. *Mol Syndromol* 2013;4:63–73.
- 90 Castori M, Rinaldi R, Capocaccia P, Roggini M, Grammatico P. VACTERL association and maternal diabetes: a possible causal relationship? *Birth Defects Res Part A Clin Mol Teratol* 2008;82:169–72.
- 91 Edison RJ, Muenke M. Mechanistic and epidemiologic considerations in the evaluation of adverse birth outcomes following gestational exposure to statins. *Am J Med Genet A* 2004;131:287–98.
- 92 Wu N, Ming X, Xiao J, Wu Z, Chen X, Shinawi M, Shen Y, Yu G, Liu J, Xie H, Gucce ZS, Liu S, Yang N, Al-Kateb H, Chen J, Zhang J, Hauser N, Zhang T, Tasic V, Liu P, Su X, Pan X, Liu C, Wang L, Shen J, Shen J, Zhang YC, Zhang J, Choy KW, Wang J, Wang Q, Li S, Zhou W, Guo J, Wang Y, Zhang C, Zhao H, An Y, Zhao Y, Wang J, Liu Z, Zuo Y, Tian Y, Weng X, Sutton VR, Wang H, Ming Y, Kulkarni S, Zhong TP, Giampietro PF, Dunwoodie SL, Cheung SW, Zhang X, Jin L, Lupski JR, Qiu G, Zhang F. TBX6 null variants and a common hypomorphic allele in congenital scoliosis. *N Engl J Med* 2015;372:341–50.
- 93 Veltman JA, Brunner HG. Understanding variable expressivity in microdeletion syndromes. *Nat Genet* 2010;42:192–3.