


ORIGINAL RESEARCH

CDK5RAP2 primary microcephaly is associated with hypothalamic, retinal and cochlear developmental defects

Hala Nasser,^{1,2} Liza Vera,³ Monique Elmaleh-Bergès,⁴ Katharina Steindl,⁵ Pascaline Letard,^{1,6,7,8} Natacha Teissier,^{6,9} Anais Ernault,¹ Fabien Guimiot,^{6,10} Alexandra Afenjar,¹¹ Marie Laure Moutard,¹² Delphine Héron,¹³ Yves Alembik,¹⁴ Martha Momtchilova,¹⁵ Paolo Milani,¹⁶ Nathalie Kubis,¹⁶ Nathalie Pouvreau,¹ Marcella Zollino ,^{17,18} Sophie Guilmin Crepon,¹⁹ Florentia Kaguelidou,²⁰ Pierre Gressens,^{6,21} Alain Verloes,^{1,6,22} Anita Rauch ,⁵ Vincent El Ghouzzi,⁶ Severine Drunat,^{1,6,22} Sandrine Passemard 

► Additional material is published online only. To view, please visit the journal online (<http://dx.doi.org/10.1136/jmedgenet-2019-106474>).

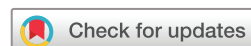For numbered affiliations see end of article.

Correspondence to

Dr Sandrine Passemard, Genetic Department, Hôpital Robert Debré, APHP, Paris, France; sandrine.passemard@aphp.fr

LV and ME-B contributed equally.

Received 5 August 2019
Revised 22 November 2019
Accepted 29 November 2019
Published Online First 3 February 2020



© Author(s) (or their employer(s)) 2020. No commercial re-use. See rights and permissions. Published by BMJ.

To cite: Nasser H, Vera L, Elmaleh-Bergès M, et al. *J Med Genet* 2020;**57**:389–399.

ABSTRACT

Background Primary hereditary microcephaly (MCPH) comprises a large group of autosomal recessive disorders mainly affecting cortical development and resulting in a congenital impairment of brain growth. Despite the identification of >25 causal genes so far, it remains a challenge to distinguish between different MCPH forms at the clinical level.

Methods 7 patients with newly identified mutations in *CDK5RAP2* (MCPH3) were investigated by performing prospective, extensive and systematic clinical, MRI, psychomotor, neurosensory and cognitive examinations under similar conditions.

Results All patients displayed neurosensory defects in addition to microcephaly. Small cochlea with incomplete partition type II was found in all cases and was associated with progressive deafness in 4 of them. Furthermore, the *CDK5RAP2* protein was specifically identified in the developing cochlea from human fetal tissues. Microphthalmia was also present in all patients along with retinal pigmentation changes and lipofuscin deposits. Finally, hypothalamic anomalies consisting of interhypothalamic adhesions, a congenital midline defect usually associated with holoprosencephaly, was detected in 5 cases.

Conclusion This is the first report indicating that *CDK5RAP2* not only governs brain size but also plays a role in ocular and cochlear development and is necessary for hypothalamic nuclear separation at the midline. Our data indicate that *CDK5RAP2* should be considered as a potential gene associated with deafness and forme fruste of holoprosencephaly. These children should be given neurosensory follow-up to prevent additional comorbidities and allow them reaching their full educational potential.

Trial registration number NCT01565005.

INTRODUCTION

Primary microcephaly (PM) is a rare neurodevelopmental disorder characterised by congenital microcephaly, intellectual disability of variable severity

(ID) and occasional epilepsy that may reflect cortical mantle defects.^{1–3}

Clinically, PM includes isolated PM (Microcephaly Primary Hereditary (MCPH), PM with short stature (Seckel syndrome, microcephalic primordial dwarfism) and syndromic PM (associated with non-neurodevelopmental manifestations). MCPH and Seckel syndrome may be further subdivided by the presence of cortical malformations and/or chorioretinopathy. Although this classification helps managing the differential diagnosis of the patients, it does not reflect underlying mechanisms. Most PMs show autosomal recessive inheritance,^{1,3} although dominant forms have occasionally been described^{4–6} and a mitochondrial origin has been proposed.⁷ To date, >100 genes have been implicated in PM.⁸

The cyclin-dependent kinase 5 (CDK5) regulatory subunit associated protein-encoding gene (*CDK5RAP2*; OMIM 608201) is among the first genes initially identified in PM (MCPH3, OMIM 604804).⁹ *CDK5RAP2* regulates CDK5 activity required for centrosome cohesion,¹⁰ centriole duplication and attachment of the centrosome to the spindle pole,¹¹ and plays a role in microtubule plus-end dynamics.¹² In addition, it is essential for DNA damage response.¹³ In the developing mouse neocortex, *Cdk5rap2* is crucial for the maintenance of apical neural progenitors^{14,15} as its deficiency leads to spindle orientation defects, premature cell cycle exit and increased cell death during neurogenesis, resulting in a reduction in the final neuron number.¹⁵ During human neurogenesis, *CDK5RAP2* is widely expressed in the ventricular and subventricular zones at the weeks of gestation WG12, WG18 and in the superficial layers of the neocortex until term.¹⁶

Variants in *CDK5RAP2* were first identified in association with PM in 2005.⁹ Since then, 35 patients from 17 families have been described, essentially through single case or mutation reports, and with limited clinical details.^{9,17–29} Most mutations reported are nonsense or frameshift variants

(ie, null variants), except for three siblings carrying missense variants²² (figure 1 and online supplementary table 1). Patients with pathogenic variants in *CDK5RAP2* display heterogeneous phenotypes: the first 11 patients reported are microcephalic individuals (Occipitofrontal circumference OFC from -4 to -9 SD during childhood) with normal stature and mild-to-moderate ID.^{9 18 26} Three infants were reported with PM and mildly short stature (from -2.5 to -4 SD) that corrected with age. Three additional patients from two pedigrees were reported with Seckel-like microcephalic dwarfism.²⁹ Feeding difficulties,^{9 20 24 26} skin areas of hypopigmentation⁹ and/or hyperpigmentation,^{21 29} seizures⁹ and deafness^{9 21 26 29} have been reported. *CDK5RAP2* variants have also been reported in patients with corpus callosum agenesis without microcephaly.²² One patient developed acute lymphoblastic leukaemia.⁹ This heterogeneity is not supported by any genotype/phenotype correlation and the possibility of additional recessive or *de novo* mutation has not been ruled out.

Despite this range of presentations, MRI data are lacking. Brain MRI performed in *CDK5RAP2* patients have failed to provide specific information. When available, data only indicate a reduced brain size and a qualitative impression of gyral simplification,^{23 26 28 29} similar to reports in other MCPH.³⁰ Hypoplasia, agenesis or dysplasia of the corpus callosum have been occasionally reported.^{21 22 24} As MRI data have not been reported for the majority of patients, the possibility that *CDK5RAP2* patients have specific brain or cortical malformations cannot be ruled out.

Furthermore, no systematic neuropsychological assessment of the patients has been published. Mild-to-moderate ID was reported in the first cases.^{9 20 31} However, this finding has been challenged by more recent studies using neuropsychological assessments^{26 28} surprisingly showing that individuals with *CDK5RAP2* variants have a normal/borderline IQ. Hence, the severe reduction in brain volume in patients with *CDK5RAP2* variants does not appear to result in an equally severe impact on cognitive functions. There is thus an urgent need for reliable data on cognitive prognosis in MCPH as a prerequisite for genetic counselling, adequate educational therapy and medical follow-up.

Here, we took advantage of a cohort of seven new *CDK5RAP2* patients, the largest series reported so far, to revisit the phenotype associated with *CDK5RAP2* by performing prospective, extensive and systematic clinical, MRI, psychomotor, neurosensory and cognitive examinations under similar conditions. We report four novel and four recently described *CDK5RAP2* mutations⁷ and show that, in addition to PM, all patients have skin pigmentation changes as well as congenital neurosensory defects, including microphthalmia and retinal pigmentation defects, and a unique cochlear malformation. In agreement with this latter finding, immuno-labelling on human fetal tissues identifies the *CDK5RAP2* protein in the developing cochlea, in addition to the fetal brain. Moreover, five patients exhibit a hypothalamic anomaly. Our data indicate that the *CDK5RAP2*-related phenotype is wider but more homogeneous than previously thought, and that ophthalmic and auditory investigations should be systematically included in the clinical follow-up of these children.

MATERIALS AND METHODS

Next-generation sequencing or targeted sequencing

Homozygosity mapping (patients 1 and 2) was performed by SNP array analysis (SurePrint G3 Human Genome CGH+SNP Microarray kit, Agilent Technologies). Coding exons and splice junctions of *CDK5RAP2* were sequenced by standard bidirectional Sanger methods. Mutations in patients 3–5 were identified

by targeted next-generation sequencing (NGS). *CDK5RAP2* was included on a microcephaly gene panel for cohort screening by multiplex PCR enrichment on a microfluidic support (Access Array, Fluidigm) and 2×150 bp sequencing with an Illumina MiSeq system. Sequencing reads were mapped to the UCSC Genome Browser (hg19) with MiSeq software, the Burrows-Wheeler Aligner and the Genome Analysis Toolkit, and panel exons were 99% covered. Variants were filtered against Mutation Annotation Form (MAF) >0.005 , dbSNP, 1000 Genomes, the NHLBI ESP Exome Variant Server and an in-house dataset. Rare variants were annotated for functional features of coding nucleotides with publicly available databases, Polyphen2, SIFT, Mutation taster and Align GVGD. Confirmation of mutations identified by NGS and their familial segregation were carried out (Sanger sequencing). Patients 6 and 7 were part of a whole-exome sequencing study in a larger microcephaly cohort. Methods, sequencing results and few clinical hallmarks of these two patients were reported elsewhere.⁷

Clinical, neuroimaging and neurosensory assessment of the patients

Seven patients carrying *CDK5RAP2* variants identified in Paris or Zurich genetic departments were recruited between 2014 and 2018. Inclusion criteria were: OFC ≤ -2 SD at birth (WHO growth charts (www.who.int/childgrowth/standards)), no environmental cause of PM. Parents provided informed consent for children's participation.

The protocol included a detailed clinical and neurological examination and the following exams/assessments:

Cerebral MRI

Included coronal T2-weighted and T1-weighted three-dimensional (3D) sequences with millimetre slices (1.5 T Philips scanner).

Cognitive assessment

Intellectual abilities were assessed using the international Wechsler scales, according to age (Wechsler Intelligence Scale for Children (WISC) IV: 6–16 years, $n=5$, patients 1, 4–7; Wechsler Preschool and Primary Scale of Intelligence (WPPSI) III: 3–7 years 7 months, $n=2$, patients 2 and 3). Full-Scale IQ (FSIQ) was calculated from four scores for WISC IV: Verbal Comprehension Index (VCI), Perceptual Organisation Index (POI), Working Memory Index (WMI) and Processing Speed Index (PSI). The scores are independent and involve specific cognitive abilities such as lexical stock, general knowledge, verbal comprehension and verbal reasoning (VCI); visuomotor and visuospatial skills to examine a problem, organise thoughts and find solutions using cubes or pictures (POI); short-term memory, concentration abilities, mental manipulation, planning abilities, cognitive flexibility, arithmetic reasoning (WMI) performance speed in graphic realisation and visual discrimination (PSI). FISQ was calculated from three scores for WPPSI III (verbal IQ, performance IQ, and processing speed quotient). Only the non-verbal reasoning scale has been calculated for patient 3 due to language barrier.

Neurosensory assessment

Ophthalmological assessment included visual acuity measurement with Snellen optotypes axial length measurement, biomicroscopy of the anterior segment and ocular fundus examination. Fundus autofluorescence imaging, full-field scotopic and photopic electroretinograms (ERGs), a pattern-ERG (pERG) and electro-oculography (EOG) were performed in all patients. Two patients underwent optical coherence tomography (3D-OCT).

Audiological assessment included pure tone and speech audiometry.

Temporal bone high-resolution CT included helical acquisition of submillimetre slices with multiplanar reconstructions (Philips Brilliance 64 CT).

Statistical analysis

The four scores required to calculate the FSIQ were compared with search for specific learning disorders (one-way analysis of variance and Bonferroni post hoc test). P values <0.05 were considered to be statistically significant.

Immunohistology in human fetal cochlea and brain

Human fetal temporal bone (1) and brain (2) specimen were obtained from morphologically normal miscarried fetuses (WG12 for (1) and WG8 and WG12 for (2)), with the informed written consent of the parents in accordance with French law. Specimen were fixed and paraffin-embedded and immunohistochemistry was performed using antibody against γ Tubulin (ab11316, Abcam), Myosin VI (M0691, Sigma) and CDK5RAP2 (A300-554A, Bethyl). Images were acquired using a Confocal Leica SP8.

RESULTS

Molecular findings

All *CDK5RAP2* mutations are depicted in [figure 1](#), [table 1](#) and online supplementary table 1.

Homozygosity mapping performed by SNP array analysis revealed a common homozygous locus including *CDK5RAP2* in patients 1 and 2 and subsequent Sanger sequencing of *CDK5RAP2* revealed a homozygous frameshift duplication of 2 bp in exon 7, leading to a premature stop codon (c.564_565dup, [p.(Lys-189Argfs*15)] [GenBank: NM_018249.5] Chr9(GRCh37):g.123,298,747_123,298,748dup). Both parents were heterozygous carriers. Gene panel analysis was performed in patients 3–5. Patient 3 was found to carry ‘assumed compound-heterozygous’ *CDK5RAP2* variants, as the parents were not available for testing: one 4 bp deletion in exon 4 (c.217_220del, [p.(Glu-73Thrfs*4)] [GenBank: NM_018249.5]; Chr9(GRCh37):g.123313156_123313159del) and a 1 bp duplication in exon 36 (c.5495dup, [p.(Leu1832Phefs*3)] [GenBank: NM_018249.5]; Chr9(GRCh37):g.123156873dup). These two variants are predicted to induce a frameshift leading to null alleles. Patients 4 and 5 displayed a homozygous pathogenic mutation in exon 12. This single nucleotide duplication creates a premature stop codon 4 codons downstream (c.1303dup, [p.(Thr435Asnfs*4)] [GenBank: NM_018249.5]; Chr9(GRCh37):g.123280713dup) predicting a null allele. The father was heterozygous carrier (no sample available from the mother).

None of the mutations found in patients 1–3 are present in public databases (gnomAD, dbSNP, 1000 Genomes, the NHLBI Exome Variant Server and the Exome Aggregation Consortium (ExAC) browser). The variant identified in patients 4 and 5 has been reported only once, in the Latino population of the gnomAD database and has never been reported in the homozygous state.

Patients 6 and 7 were found to be compound heterozygous for truncating variants by trio whole-exome sequencing as recently described.⁷ Each patient carried one unreported variant and one with a very low minor allele frequency, both heterozygous, in the ExAC/gnomAD databases. Patient 6 harboured NM_018249.5(CDK5RAP2):c.[558_559delGA]+[c.4441C>T], p.[(-Glu186Aspfs*32)]+[(-Arg1481*)], Chr9(GRCh37):g.

[123298753_123298754del];[123171568C>T] with the mother heterozygously carrying c.[558_559delGA]+[=], p.[(-Glu186Aspfs*32)]+[=] (unreported) and the father heterozygously carrying c.[c.4441C>T]+[=], p.[(-Arg1481*)]+[=] (rs587783390; ExAC: A=0.00005660/4, no homozygotes). Patient 7 harboured NM_018249.5(CDK5RAP2):c.[3928G>T];[4546G>T] p.[(-Glu1310*)];[(-Glu1516*)] Chr9(GRCh37):g.[123199600C>A];[123171463C>A] with the mother heterozygously carrying c.[4546G>T];[=] p.[(-Glu1516*)];[=] (rs374351172; ExAC: A=0.00002472/3, no homozygotes, gnomAD: A=0.00002844/7, no homozygotes) and the father heterozygously carrying c.[3928G>T];[=] p.[(-Glu1310*)];[=] (unreported).

Clinical characteristics

Clinical details are summarised in [table 1](#). Microcephaly was confirmed at birth in all cases and was even detectable during the second or third trimester of pregnancy in five out of seven patients before reaching a mean occipitofrontal circumference (OFC) of -6 ± 1.7 SD during infancy. Nevertheless, an unusual improvement of the OFC after age 2 for patients 1, 2 and 4 was noted (online supplementary figure 1). None of the patients had short stature beyond age 5. Areas of hypopigmentation or hyperpigmentation of the skin were systematically found in all patients. Motor development was also normal. Suspected around age 3 because of speech delays, the main functional consequence of brain volume reduction and simplified gyri, both obvious on brain MRI (online supplementary figure 2), was ID, ranging from mild to moderate (FSIQ from 40 (patient 5) to 67 (patient 1), see online supplementary figure 3). We cannot exclude the possibility that patient 5, with moderate ID may have a second hit related to the context of consanguinity. However, in all patients, a relative preservation of verbal comprehension (VCI 78 and 75 for patients 1 and 2) and visuospatial abilities (71 and 75 for patients 2, 3 and 6) as well as a preservation of mental manipulation was detected (78 and 73 for patients 1 and 4). None of the patients exhibited epilepsy.

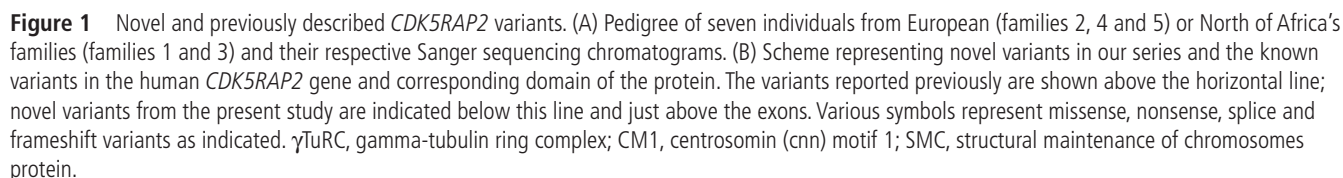
Developmental hypothalamic defect

Patients 1, 2, 4, 5 and 7 displayed interhypothalamic adhesion (IHA), a grey matter band that connects the dorsomedial and ventromedial hypothalamic nuclei and/or arcuate, paraventricular or preoptic nuclei on both sides of the third ventricle³² ([figure 2](#)). IHA differs from hamartoma as it does not extend into the third ventricle. For patient 6, brain MRI was performed with another protocol including a series of 5 mm slices without T1-weighted 3D sequence, which did not allow to formally identify IHA. IHA was already noticed on the brain MRI performed at 1 year of age in patient 1, and was not enhanced after gadolinium injection, as classically described for glioma, another differential diagnosis of IHA. Taken together, these observations suggest that IHA, which is present at least in five out of seven patients, may be caused by a failure of the separation of hypothalamic nuclei at early developmental stages.

Neurosensory impairment

Microphthalmia and retinal pigmentation defects

Ophthalmological assessment showed normal biomicroscopy and no oculomotor disorder. The axial length was below the normal range in all patients (average: 20.9, from 20.3 to 22.3 mm; normal age >3 years: 23.5 mm) ([tables 1 and 2](#), [figures 3 and 4](#)).



All patients being hyperopic, best-corrected visual acuity was 20/20 except in the youngest patient (patient 3), aged 4 years and non-cooperative, whose visual acuity was superior to 20/40 in each eye. Scotopic and photopic flash ERGs as well as the EOG and pERG were similar to age-matched controls (data not shown).

Table 1 Clinical and molecular findings of patients with *CDK5RAP2* mutations

Family	1	1	2	3	3	4	5
Subject	Patient 1	Patient 2	Patient 3	Patient 4	Patient 5	Patient 6	patient 7
Gender	M	F	F	F	M	M	F
CDK5RAP2 variant	c.564_565dup (p.Lys189Argfs*15)	c.564_565dup (p.Lys189Argfs*15)	c.5495dup, (p.Leu1832Phefs*3) ; c.217-220del, (p.Glu73Thrfs*4)	c.1303dup (p.Thr435Asnfs*4)	c.1303dup (p.Thr435Asnfs*4)	c.558_559del, (p.Glu186Aspfs*32) ; c.4441C>T, (p.Arg1481*)	c.3928G>T, (p.Glu1310*) ; c.4546G>T, (p.Glu1516*)
Ethnic origin	Tunisia	Tunisia	Serbia	Morocco	Morocco	Italian/Romanian	Swiss/Austrian
Consanguinity	Yes	Yes	Yes	Yes	Yes	No	No
Mother HC (cm, SD)	56 (+1)	56 (+1)	54.5 (0)	Not available	Not available	53 cm	Not available
Father HC (cm, SD)	60 (+3.5)	60 (+3.5)	57.5 (+1.5)	Not available	Not available	58.5 cm	Not available
Pregnancy duration (weeks of amenorrhoea)	38	40	39	39	38	41	39
Prenatally diagnosed microcephaly (ultrasounds)	Third trimester	Second trimester	Non-reported microcephaly	Non-reported microcephaly	Third trimester	Second trimester	Third trimester
Fetal cranial MRI	Not performed	Not performed	Not performed	Not performed	Not performed	Not available	Not performed
Weight at birth (kg, SD)	2.490 (−2)	3.160 (−0.5)	2.965 (−1)	2.260 (−2.5)	1.520 (−3.5)	2.900 (−1.5)	2.005 (−3)
Length at birth (cm, SD)	45 (−3.5)	45 (−3)	47 (−2.5)	45 (−3)	41 (−5.5)	46 (−3)	44 (−3)
HC at birth (SD)	31 (−2.2)	30.5 (−2.5)	30.5 (−2.5)	29.5 (−3)	26.5 (−5)	30.5 (−2.5)	28 (−4)
Age at last examination (years)	10	4.5	4.5	11	10	8	14.5
Weight at last examination (kg, SD)	52.5 (+5.5)	12.5 (−2)	19.5 (+2)	48.3 (+3)	21.5 (−2)	26 (+0.5)	34.3 (−3)
Length at last examination (m, SD)	1.34 (0)	0.94 (−2)	1.07 (+1)	1.44 (+0.5)	1.27 (−1.5)	118 (−1.5)	146.4 (−2)
HC at last examination (cm, SD)	48.5 (−3.4)	42 (−6.6)	42.5 (−6.2)	47.5 (−4)	42 (−7.7)	42.8 cm (−7.2)	43.2 (−7.3)
Development							
Age of walking (months)	10.5	16	14	11	18	12	18
Mastication (if delayed, age in months)	Delayed (24)	Delayed (24)	Normal	Normal	Delayed (24)	Delayed (30–36)	Normal
Age of first comprehensive words (months)	18	18	30	24	54	18	21
Age of first sentences (years)	4.5	2	4.5	3	Unvested, severe articulation disorders	8	3.5
Language articulation (normal, delayed)	Normal	Normal	Delayed	Normal	Delayed	Delayed (30 mo)	Delayed
Social interaction (normal/delayed)	Normal	Normal	Normal	Normal	Normal	Normal	Normal
Years in kinder garden	3	0	1				
Elementary school	First year in normal class, then home schooling						
Seizures	0	0	0	0	0	0	0
Neurological findings							
Hypertonia within the first 2 years of life	0	0	0	0	0	Yes	Yes
Hypotonia within the first 2 years of life	0	0	0	0	0	No	Axial hypotonia
Pyramidal syndrome	0	0	0	0	0	No	0
Inferior limb spasticity	0	0	0	0	0	Yes	Yes
Ataxia	0	0	0	0	0	Incoordinate movements	Yes
Behaviour							
Hyperactivity	Yes	Yes	Yes	Before 7–8 years	Before 7–8 years	Quiet behaviour, but hyperactivity episodes	No
Tic disorders	No	No	No	No	0	(but repetitive movements)	No
Agressiveness	No	No	No	No	0	Episodes of aggressiveness	No
Intellectual abilities							
Total IQ	62	67		40	56	52	46
Sensorineural anomalies							
Congenital hearing loss (unilateral/bilateral)	No	No	No	No	No	0	No
Progressive hearing loss (uni/bilateral), age	Bilateral, 9 years	No	Unilateral, 7 years	No	Bilateral, 7 years	Bilateral, 10 years	No
Hearing (auditory threshold)	Right: severe deafness (70–80 dB) Left: moderate deafness (20–50 dB)	Normal oto-acoustic emissions within the first months of life	Right: severe deafness (70 dB) Left: normal	Right: normal (15–20 dB) Left: normal (15–25 dB)	Right: severe deafness (80–90 dB) Left: severe deafness (60–70 dB)	Right: severe deafness (60–80 dB) Left: moderate-to-severe deafness (40–60 dB/60–80 dB)	Right and left: normal
Hearing aid (unilateral/bilateral)	Unilateral	No	Unilateral	No	Bilateral	Bilateral	No
Retinal hypopigmentation (unilateral/bilateral)	Bilateral	Bilateral	Bilateral	Bilateral	Bilateral	?	Yes
Retinal hyperpigmentation (unilateral/bilateral)	Bilateral	Bilateral	Bilateral	Bilateral	Bilateral	?	No
ERG	Normal	Normal	Normal	Normal	Normal	Not done	Normal
Skin anomalies							
Area of hypopigmentation	Yes	Yes	Yes	No	No	No	Yes
Area of hyperpigmentation	Yes	Yes	No	Yes	Yes	Yes (several café-au-lait spots on trunk, arms and legs)	Yes

CC, corpus callosum; ERG, electroretinogram; HC, head circumference; IQ, intellectual quotient.

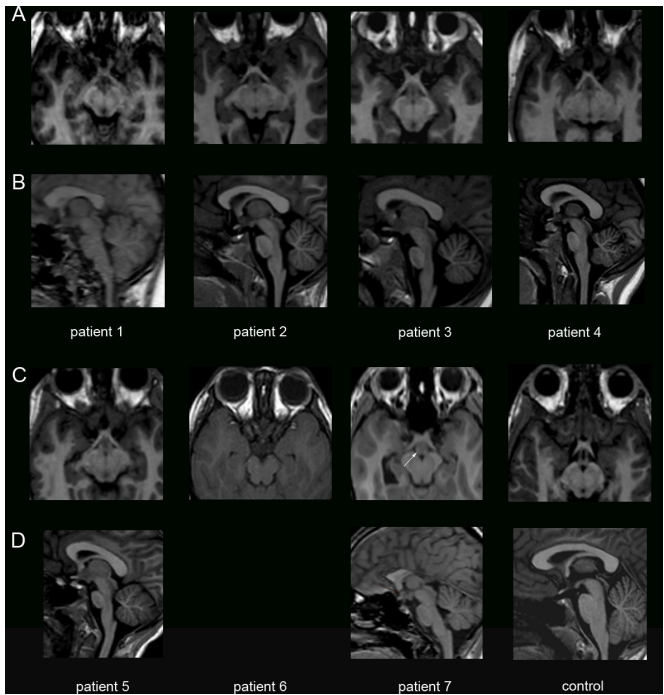


Figure 2 Developmental hypothalamic defects in patients with *CDK5RAP2* variants. Coronal (A, C) and sagittal (B, D) T1-weighted images showing in patients 1, 2, 4, 5 and 7 a structure iso-intense to grey matter consistent with an interhypothalamic adhesion (IHA, white arrows), and absent in the healthy control. This grey matter band on coronal view and nodular on sagittal view is located at the level of the upper midbrain, closed to the anterior/inferior third ventricle. IHA is known to connect both dorsomedial and ventromedial hypothalamic nuclei and/or arcuate, paraventricular or pre-optic nuclei on both sides of the third ventricle.

Progressive hearing loss associated with congenital inner ear malformation

Patients 1, 3, 5 and 6 developed progressive unilateral or bilateral hearing loss, respectively diagnosed at age 9, 6, 7 and 10

(table 1). Audiometric evaluations at diagnosis showed severe hearing loss from 70 to 80 Hz in at least one ear for all four patients. Patient 1 had a unilateral scotoma of the left ear at 6000 Hz at 60 dB, and a 77.5 dB threshold in the right ear (figure 4B–C). Close to normal hearing levels were restored with conventional hearing aids. However, patient 5 did not receive early intervention/rehabilitation. This delayed medical support is likely to have increased the receptive and expressive speech impairment caused by PM itself and worsened ID. Surprisingly, although they had been stable for at least 4 years, patient 1 has recently undergone an improvement of his auditory thresholds, which is now at 42 dB in the right ear and 26 dB in the left ear on average, with a concordant vocal threshold.

As sensorineural hearing loss (SNHL) is very unusual in patients with PM, a temporal bone CT scan was performed for all patients except patient 6 (parental rejection), and revealed the same cochlear malformation in each case: small cochlea compared with normal values on CT³³ and an absence of the interscalar septa at the apical turn (figure 4A and table 2), that is, compatible with the diagnosis of incomplete partition type II of the Sennaroglu classification.³⁴ In addition, patient 2 displayed an enlarged vestibular aqueduct associated with this cochlear dysplasia. In all patients, the diameter of the bony cochlear nerve canal was reduced (<1.7 mm), in favour of a cochlear nerve hypoplasia.³³

CDK5RAP2 detection in the fetal cochlear epithelium

The CDK5RAP2 protein is known to be expressed in the ventricular zone (VZ) of both mouse and human telencephalon throughout neurogenesis.¹⁶ However, its presence in the inner ear has not been documented so far. Using immunohistochemistry for CDK5RAP2 on human fetal tissues, we found that it is expressed in the developing cochlea in addition to the fetal brain. Co-labelling of CDK5RAP2 with γ -tubulin on human fetal brain sections at early (WG8) and mild (WG12) stages of neurogenesis confirmed that CDK5RAP2 is highly expressed at the centrosome of the apical radial glial cells (aRGCs) of the VZ (online supplementary figure 4). Immunolabeling on human

Table 2 Neuroradiological findings of patients with *CDK5RAP2* mutations

Neuroradiological findings	Patient 1 10 years		Patient 2 4.5 years		Patient 3 4.5 years		Patient 4 11.5 years		Patient 5 10 years		Patient 6 5 years		Patient 7 13.75 years	
	Raw measure	3rd percentile	Raw measure	3rd percentile	Raw measure	3rd percentile	Raw measure	3rd percentile	Raw measure	3rd percentile	Raw measure	3rd percentile	Raw measure	3rd percentile
Corpus callosum (CC)														
APD (mm)	45.7	(59.1)	47.91	(55.5)	42.43	(55.5)	55.86	(59.7)	49.06	(59.1)	30.09	(56.2)	29.39	(61.7)
Cranial FOD (mm)	121.6	(148.6)	113.2	(140.5)	113	(140.5)	130.1	(145)	114.5	(148.6)	113	(142.3)	125	(147.5)
APD/FOD	0.37	(0.37)	0.42	(0.36)	0.37	(0.36)	0.42	(0.37)	0.42	(0.37)	0.27	(0.36)	0.23	(0.38)
GT (mm)	9.48	(7.3)	7.25	(6.7)	7.36	(6.7)	8.72	(7.4)	7.96	(7.3)	6.2	(6.9)	7.22	(7.6)
BT (mm)	7.42	(4)	5.39	(3.5)	6.93	(3.5)	5.46	(4)	6.42	(4)	7.8	(3.7)	5.23	(3.9)
IT (mm)	7.3	(2.4)	4.82	(1.9)	6.02	(1.9)	6.14	(2.4)	6.32	(2.4)	6	(2)	4.6	(2.5)
ST (mm)	9.09	(7.7)	10.02	(6.7)	8.11	(6.7)	11.17	(7.7)	10.13	(7.7)	3.9	(6.9)	0	(7.1)
Gyration	Simplified		Simplified		Simplified		Simplified		Simplified		Simplified		Simplified	
Interhypothalamic adhesions	Yes		Yes		No		Yes		Yes		?	Midline sagittal sections>5 mm	Yes	
Internal ear	Type II incomplete partition of the cochlea		Type II incomplete partition of the cochlea Enlarged right vestibular aqueduct		Type II incomplete partition of the cochlea		Type II incomplete partition of the cochlea		Type II incomplete partition of the cochlea		Not performed		Type II incomplete partition of the cochlea	

Adapted from Garel et al, 2011.⁵⁰

APD, anteroposterior diameter of the corpus callosum; BT, body thickness; FOD, fronto-occipital diameter; GT, genu thickness; IT, isthmus thickness; ST, splenium thickness.

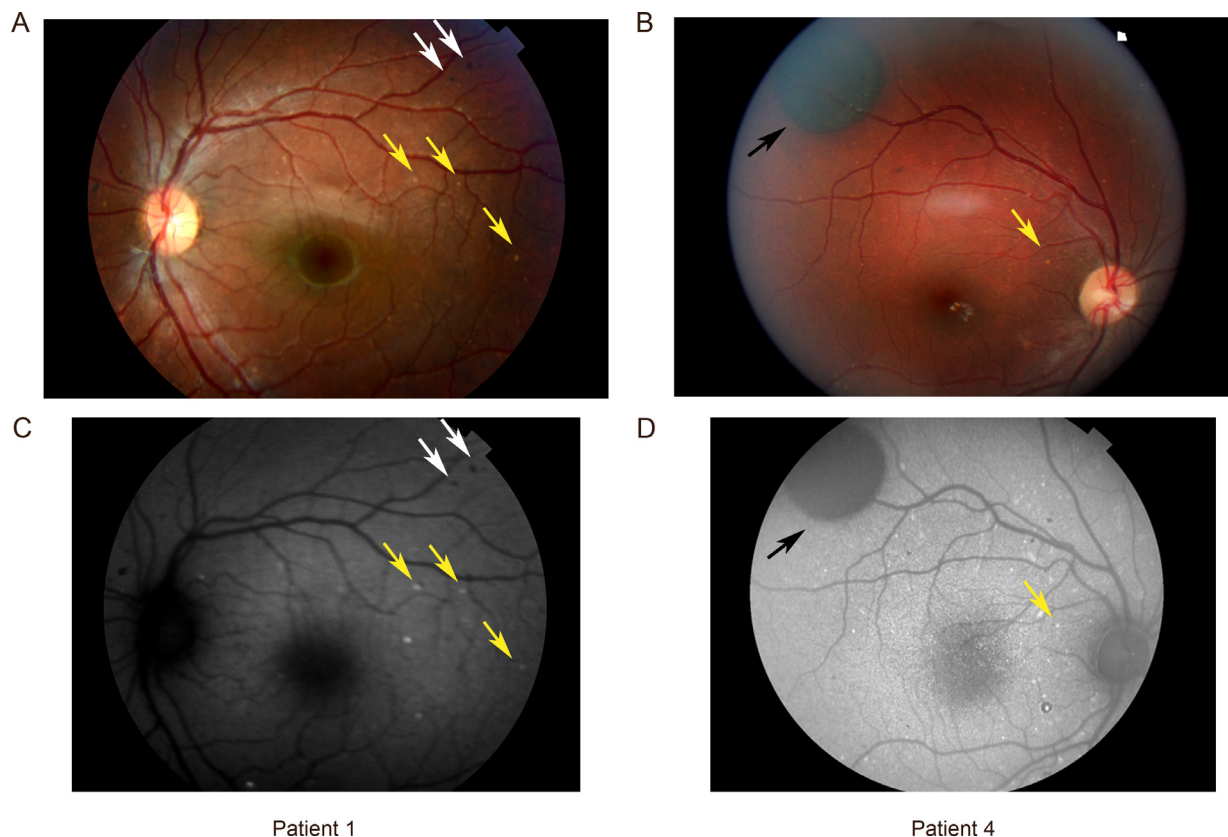


Figure 3 Retinal pigmentary changes in patients with *CDK5RAP2* variants. (A, B) Ocular fundus photography of patients 1 and 4 showing focal regions of hyperpigmentation and hypopigmentation in the retinal pigment epithelium (RPE). Note that hyperpigmented lesions appeared as small dark spots (patient 1, white arrows) or dark grey extended lesions (patient 4, black arrow) and were located in the macular zone and/or in the retinal periphery. Small round spots of hypopigmentation were scattered in the posterior pole (yellow arrows in patients 1 and 4). (C, D) Ocular fundus autofluorescence showing that hyperpigmented lesions appear as well-defined patches of hypoautofluorescence (figure 3C–D, white and black arrows), whereas hypopigmented spots appear as areas of hyperfluorescence, reminiscent of lipofuscin deposits/accumulation in the RPE in both patients (yellow arrows).

fetal cochlea at WG12 showed that *CDK5RAP2* is expressed in MYOSIN VI (a protein expressed in the cytoplasm of outer hair cells of the organ of Corti) positive cells (figure 4F (and Figure 4 D–E for low magnification)). At the apical pole of these outer hair cells, *CDK5RAP2* was also co-expressed with γ -tubulin (figure 4G) at the centrosome, concordant with its expression within the VZ. Thus, *CDK5RAP2* is expressed early at the centrosome in the sensory epithelium of the organ of Corti as in the neuroepithelium.

DISCUSSION

In this study, we identify neurosensory impairments associated with the *CDK5RAP2* microcephaly, including retinal pigmentation defects and a specific cochlear malformation responsible for progressive sensorineural hearing loss. All patients examined with our protocol displayed IHA, suggesting a failure in hypothalamic nuclei separation. *CDK5RAP2* is thus crucial for neurosensory development in addition to brain development.

CDK5RAP2 and brain development

In agreement with the congenital defects observed, *CDK5RAP2* is highly expressed during human neurocorticalogenesis. Although the protein has been detected from WG18 onwards,¹⁶ we find that *CDK5RAP2* is present as early as WG8 in the VZ of the human fetal cortex, at the centrosome of aRGs. This highlights *CDK5RAP2* requirement for early progenitors' division and may explain why microcephaly is often detected antenatally.

Similarly, aRGs switch from symmetric (proliferative) to asymmetric (neurogenic) division in *Cdk5rap2*-deficient mice, which results in premature cell cycle exit, increased cell death and a reduced number of cortical neurons.¹⁵

Interestingly, OFC suddenly increased after age 2 in three patients (online supplementary figure 1), a phenomenon not previously reported in PM. The partial compensation observed could result from postnatal white matter development, myelination and/or synaptogenesis.^{35–36} Brain MRI early follow-up, including T2-weighted images and tractography should therefore be envisioned to assess myelination and synaptogenesis in *CDK5RAP2* patients. Despite the reduction in neuron number, it is possible that neurons that have reached maturity manage developing a fairly efficient network, a situation that would be consistent with the mild ID observed, unlike patients with PM due to *ASPM* mutations who have more pronounced ID.³⁰ In agreement with this assumption, patients whose OFC increases after age 2 also showed a higher IQ. Larger cohorts would greatly help validating this hypothesis.

IHA was detected in five patients. This band of grey matter connects hypothalamic nuclei from the two sides of the third ventricle may be similar to a forme fruste of holoprosencephaly (HPE), which is restricted to the ventral part of the diencephalon and characterised by the non-separation of hypothalamic nuclei along the midline without fusion of the thalami. IHA is often associated with other CNS midline defects including corpus callosum dysgenesis, as seen in patients 6 and 7, or other defects

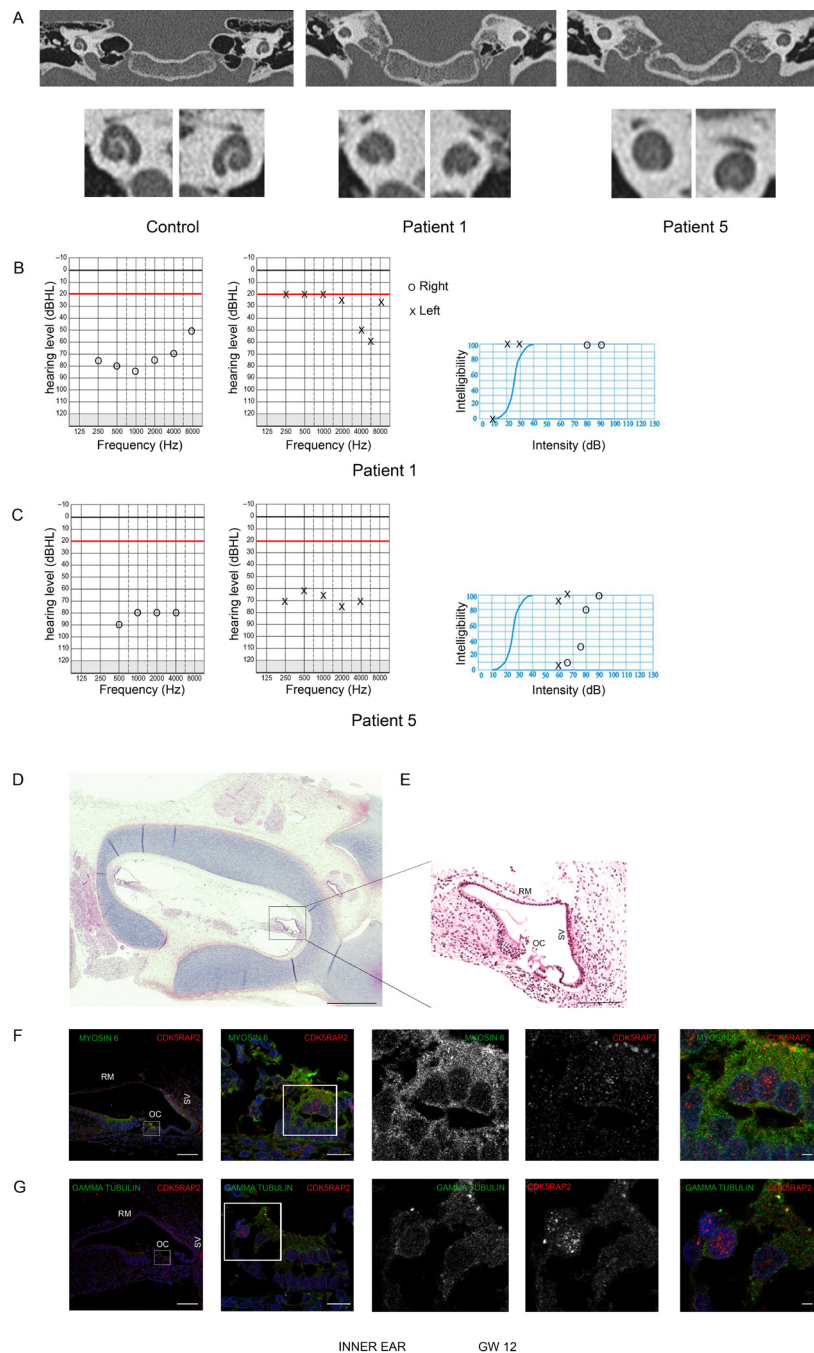


Figure 4

Figure 4 Congenital inner ear malformation responsible for progressive deafness in patients with *CDK5RAP2* variants. (A) Temporal bone coronal CT scan images in patient 1 and 5 showing small cochlea with no visibility of the interscalar septa at the apical turn of the cochlea and a confluence of middle and apical turns of the cochlea, evocative of an incomplete partition type II according to Sennaroglu classification. (B, C) Tonal and vocal audiograms of patients 1 (B) and 5 (C). Circles and X symbolise joint air and bone-conducted hearing thresholds, respectively for right and left ears. (B) On the right ear, the ascending curve corresponds to a severe hearing loss whereas the left ear demonstrates a normal hearing threshold for conversational frequencies associated with a scotoma at 6000 Hz. (C) The mean hearing threshold of 80 dB on the right ear and 70 dB on the left ear indicate a bilateral hearing loss. (D, E) Horizontal section of temporal bone (D) of a control fetus at WG12 stained by H&E and high magnification on the cochlea (E) highlighting the structure of a normal fetal cochlea. RM, Reissler's membrane; OC, organ of Corti; SV, stria vascularis. Scale bars: 25 mm (D), 500 µm (E). (F, G) Immunohistochemistry in the adjacent section of the cochlea of the control fetus at WG12 shown in (D). White squares indicate regions of the cochlea that are shown in higher magnification in the right part of the panel. (F) Co-labelling of *CDK5RAP2* (red) and myosin VI (green, that stains the outer hair cells of the cochlea) and DAPI (blue) showing that *CDK5RAP2* is expressed in myosin VI positive cells at the apical pole of outer hair cells. (G) Co-labelling of *CDK5RAP2* (red) and gamma-tubulin (green, that stains the pericentriolar material at the centrosome) demonstrating that *CDK5RAP2* is localised at the centrosome of the outer hair cells of the cochlea. Scale bars: 90 µm (first left panel), 15 µm (second left panel), 15 µm (right panel).

not observed in our patients such as an absence of the septum pellucidum, optic pathway hypoplasia, hippocampal dysgenesis.^{32,37} However, IHA may also occur as an isolated asymptomatic feature.³² At their last examination, the children of our series did not exhibit any obvious endocrine disorder attributable to the hypothalamic defect: growth was within the normal range for weight and height; no diabetes insipidus or high blood pressure was noted. Although no micropenis was detected, tracking puberty onset would be relevant. Interestingly, patients 1 and 4 showed excessive weight gain (after age 8 and 9, respectively). During the second decade of life, we propose to assess energy metabolism in these patients.

PM and HPE have already been associated in patients carrying variants in the MCPH7 gene *STIL*.³⁸ These patients exhibit a mild lobar form of HPE and PM with gyral simplification and interhemispheric cysts. This suggests that, as for *STIL*, *CDK5RAP2* can be added to the list of genes causing a forme fruste of HPE in humans.

CDK5RAP2 and ear development

We show here that *CDK5RAP2* loss of function affects the development of extracortical regions and results in a broader phenotype than just microcephaly. This observation is consistent with the pattern of expression of *CDK5RAP2*, which encompasses the cortical VZ and subventricular zones and the spiral organ of Corti, and indicates that this centrosomal protein is critical to the development and maintenance of neurosensory functions.

Malformations of the inner ear are found in 30%–40% of children with SNHL on imaging (CT, MRI).^{33,39,40} Incomplete partition of the cochlea type II³⁴ refers to a cochlea that has a normal basal turn but a cystic apex with hypoplasia of the modiolus and absence of the interscalar septum. This malformation was obvious in all examined patients. Patient 2 also showed a dilated vestibule and vestibular aqueduct enlargement (Mondini dysplasia). Incomplete partition of the cochlea type II is a congenital cause of sensorineural hearing loss. This cochlear malformation typically occurs during WG7.⁴¹ Hearing loss may be mild to profound and must be evaluated with systematic audiometry. As *CDK5RAP2* variants described in the present study have not been reported previously, one cannot rule out the possibility that the associated neurosensory impairments are variant-specific. However, hearing loss has been occasionally mentioned in previous *CDK5RAP2* patients carrying other variants^{19,26} and our systematic study suggests that the neurosensory defects are likely constitutive of the *CDK5RAP2* phenotype and may have been overlooked in previously reported cases.

The most common aetiology of Mondini dysplasia is a variation in the *SLC26A4* gene involved in Pendred syndrome^{42,43} and in a non-syndromic hearing loss,⁴⁴ but variants in >100 genes cause severe congenital or progressive hearing loss.⁴⁵ Genes involved in genetic SNHL encode proteins playing a role in gene regulation, fluid homeostasis, synaptic transmission and hair cell and neuronal maturation, and in stereocilia function.⁴⁵ To date, no interaction between such proteins and *CDK5RAP2* has been reported. In humans, the cochlea develops between WG6–7 and 10–12, and the vestibule between WG9 and 13,⁴¹ that is, at the beginning of neurogenesis. It has been shown that the brain volume reduction related to *Cdk5rap2*-deficient mice is due to reduced neural progenitor proliferation, cell death and early neuronal differentiation during neurogenesis.¹⁵ It is thus possible that the observed simplification of the cochlear spiral also reflects defective proliferation or cell death leading to a depletion of the pool of progenitors and the early differentiation

of the cochlear epithelium. Given that hearing loss was not congenital and was identified when the youngest patient was 6 years of age, we recommend that audiograms be performed systematically at the time of diagnosis, and possibly, repeated on a yearly basis. Neurosensory management of these patients is crucial as it considerably impacts communication, learning and integration abilities.

CDK5RAP2 and eye development

PM is not commonly associated with microphthalmia except in specific syndromes such as Warburg-Micro syndrome (#600118, *RAB3GAP1*, #614225, *RAB3GAP2*, #614222, *RAB18*, #615623, *TBC1D20*), microcephaly and chorioretinopathy type 3 (#616335, *TUBGCP4*⁴⁵) or type 6 (#251270, *TUBGCP6*⁴⁶) or microcephaly with or without chorioretinopathy, lymphoedema and mental retardation (#152950, *KIF11*⁴⁷). In the present study, we have shown that microphthalmia is a cardinal feature of the *CDK5RAP2*-associated phenotype, and confirms in humans what Zaout et al have recently shown in *Cdk5rap2* mutant mice (an/an).⁴⁸ More surprising were the retinal pigmentation changes found in all the patients. Retinal hyperpigmentation could be related to skin hyperpigmentation spots. Hypopigmented spots that are hyperautofluorescent are reminiscent of lipofuscin deposits/accumulation in the retinal pigmentary epithelium (RPE). No functional consequences on visual acuity or ERG were noticed. OCT was normal for both patients tested, suggesting that lipofuscin accumulation does not alter the RPE-photoreceptor layer. Our patients still being children, their ophthalmological status obviously needs to be reassessed to check whether lipofuscin deposits are stable or increase with time and/or impact visual function. These retinal pigmentation changes do not resemble the well-characterised chorioretinopathies associated with microcephaly such as those caused by *PLK4*, *TUBGCP6* (#251270⁴⁶), *TUBGCP4* (#616335⁴⁵) or *KIF11* (#152950⁴⁷) variants. We propose that this new entity, which resembles that described by Abdel-Saam et al prior to gene identification,⁴⁹ may be related to *CDK5RAP2* variants, because it is present in all patients of the present series.

CONCLUSION

Overall, our findings extend the phenotype associated with *CDK5RAP2* microcephaly and indicate that MCPH3 is distinct from other MCPH by its association with neurosensory impairment. These results shed new light on the role of *CDK5RAP2* in brain, ear and eye development and maturation.

Author affiliations

- ¹Département de Génétique, APHP, Hôpital Robert Debré, 75019 Paris, France
- ²Service des Explorations Fonctionnelles, APHP, Hôpital Robert Debré, 75019 Paris, France
- ³Service d'Ophtalmologie, APHP, Hôpital Robert Debré, 75019 Paris, France
- ⁴Service de Radiologie Pédiatrique, APHP, Hôpital Robert Debré, 75019 Paris, France
- ⁵Institute of Medical Genetics, University of Zurich, Schlieren-Zurich, Switzerland
- ⁶Université de Paris, NeuroDiderot, Inserm, F-75019 Paris, France
- ⁷Service d'Anatomopathologie, Hôpital Jean Verdier, APHP, Bondy, France
- ⁸Université Paris 13, 93140 Bondy, France
- ⁹Service d'ORL, APHP, Hôpital Robert Debré, 75019 Paris, France
- ¹⁰Service de Foetopathologie, APHP, Hôpital Robert Debré, 75019 Paris, France
- ¹¹CRM déficiences intellectuelles de causes rares, Département de génétique, Sorbonne Université, APHP, Hôpital Trousseau, 75012 Paris, France
- ¹²Service de Neuropédiatrie, APHP, Hôpital Trousseau, 75012 Paris, France
- ¹³Département de Génétique, APHP, Hôpital La Pitié-Salpêtrière, 75013 Paris, France
- ¹⁴Service de Génétique Médicale, CHU de Strasbourg, Hôpital de Hautepierre, 67200 Strasbourg, France
- ¹⁵Service d'Ophtalmologie, APHP, Hôpital Trousseau, 75012 Paris, France
- ¹⁶Service des Explorations Fonctionnelles, APHP, Hôpital Lariboisière, 75010 Paris, France

- ¹⁷Università Cattolica Sacro Cuore Istituto di Medicina Genomica, Roma, Italy
¹⁸Fondazione Policlinico A. Gemelli IRCCS, Roma, Italy
¹⁹Unité d'Epidémiologie Clinique, APHP, Hôpital Robert Debré, 75019 Paris, France
²⁰Université de Paris, Centre d'Investigation Clinique, CIC 1426, INSERM, APHP, Hôpital Robert Debré, 75019 Paris, France
²¹Center for Developing Brain, King's College, St. Thomas' Campus, London, United Kingdom
²²European Reference Network ERN ITHACA, 75019 Paris, France
²³Service de Neuropédiatrie, APHP, Hôpital Robert Debré, 75019 Paris, France

Acknowledgements The authors would like to thank all patients and their family. The authors would like to thank the CIC team (CIC 1426, Inserm) at Robert Debré Hospital in Paris who organised the families' visit and ensured the implementation of the clinical research protocol. The authors would also like to thank Dr Sowmyalakshmi Rasika for relevant comments and language editing during the preparation of this manuscript.

Contributors HN analysed and interpreted all clinical data. LV and NT analysed the ocular and ENT phenotypes, respectively for all patients with the help of MM. ME analysed brain MRI and temporal bone CT scan for all patients. HN, LV, NT and ME helped writing the manuscript. AE performed the neuropsychological assessment for all patients. KS, AA, MLM, DH, YA and MZ were involved in patient recruitment and clinical management. SGC and FK conducted the research protocol. PL and FG performed the immunostaining in human tissues. VEG, AV and PG revised and edited the manuscript. SD and AR analysed and interpreted NGS data and performed segregation analysis. SP conceived the study, interpreted the results and wrote the manuscript.

Funding This work was supported by the Délégation à la Recherche Clinique et à l'Innovation de l'Assistance Publique Hôpitaux de Paris, the Institut National pour la Santé et la Recherche Médicale (Inserm), the Université Paris 7, the Centre National de la Recherche Scientifique (CNRS), the DHU PROTECT, the Programme Hospitalier de Recherche Clinique (PHRC, grant agreement n° P100128/IDRCB: 2010-A01481-38), by ERA-NET grant 'Euromicro' (ANR-13-RARE-0007-01, ANR-16-CE16-0024-01 to SP, AV, VE, SD and PG and SNF 31ER30_154238 to AR) and radiz-Rare Disease Initiative Zurich, clinical research priority programme, University of Zurich.

Competing interests None declared.

Patient consent for publication Not required.

Ethics approval The trial was approved by the National Ethics Committee (Comité de Protection des Personnes (CPP) Ile-de-France II).

Provenance and peer review Not commissioned; externally peer reviewed.

Data availability statement Data are available on reasonable request. Data used in the manuscript are available by request to the authors.

ORCID iDs

Marcella Zollino <http://orcid.org/0000-0003-4871-9519>

Anita Rauch <http://orcid.org/0000-0003-2930-3163>

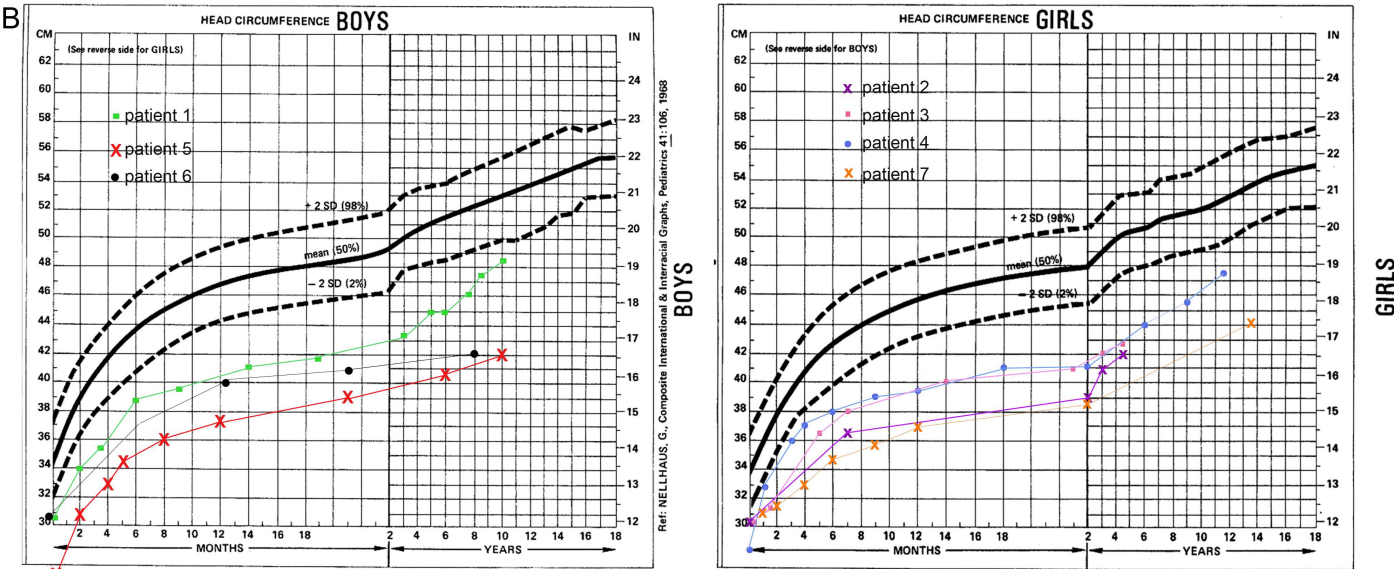
Sandrine Passemard <http://orcid.org/0000-0002-0242-4566>

REFERENCES

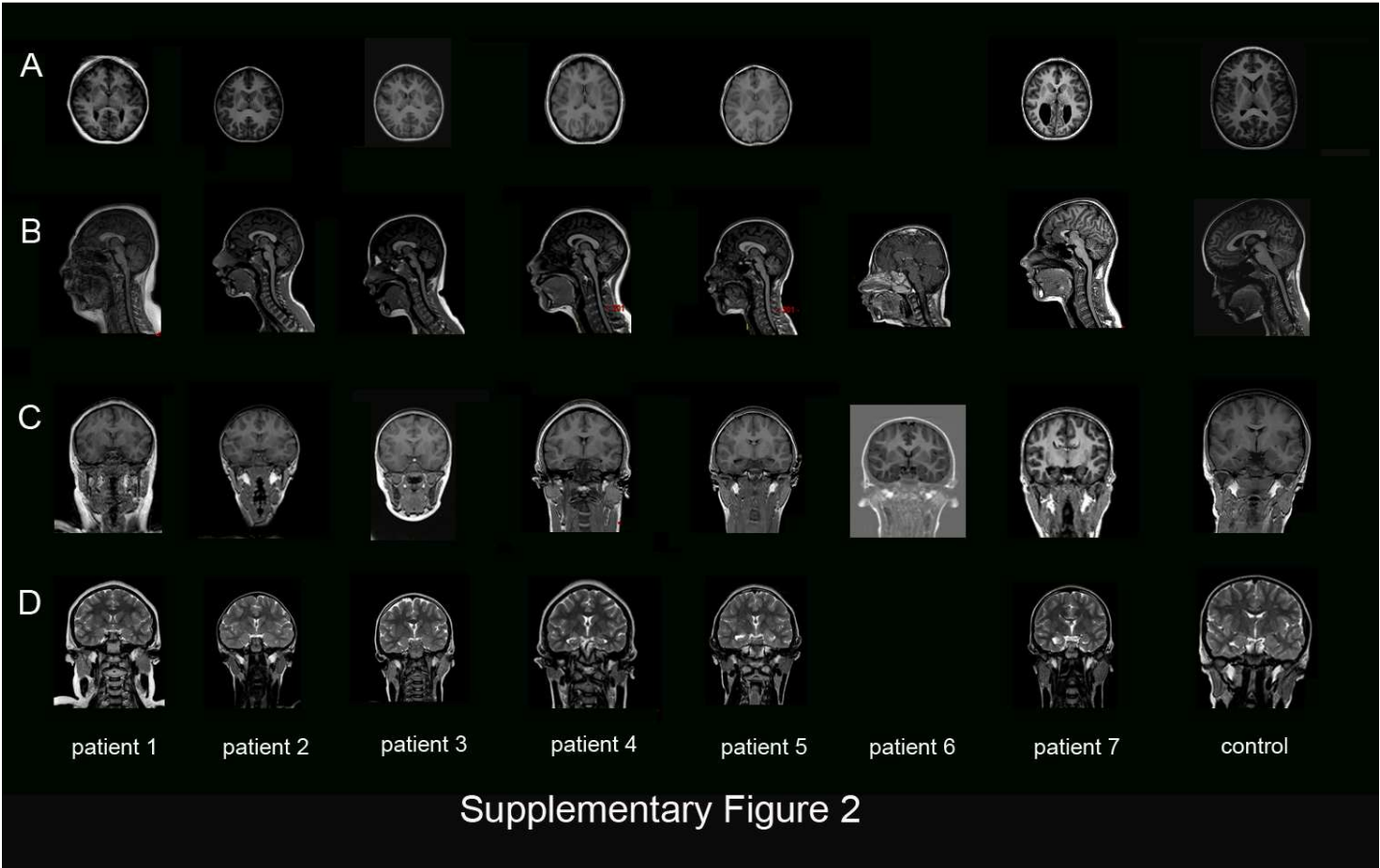
- Kaindl AM, Passemard S, Kumar P, Kraemer N, Issa L, Zwirner A, Gerard B, Verloes A, Mani S, Gressens P. Many roads lead to primary autosomal recessive microcephaly. *Prog Neurobiol* 2010;90:363–83.
- Thornton GK, Woods CG. Primary microcephaly: do all roads lead to Rome? *Trends Genet* 2009;25:501–10.
- Verloes A, Drunat S, Gressens P, Passemard S. Primary Autosomal Recessive Microcephalies and Seckel Syndrome Spectrum Disorders. In: Pagon RA, Adam MP, Ardinger HH, Wallace SE, Amemiya A, Bean LH, Stephens K, eds. *GeneReviews* 2013. (NBK9587 [bookaccession]). Seattle, 1993.
- Izumi K, Brett M, Nishi E, Drunat S, Tan E-S, Fujiki K, Lebon S, Cham B, Masuda K, Arakawa M, Jacquinet A, Yamazumi Y, Chen S-T, Verloes A, Okada Y, Katou Y, Nakamura T, Akiyama T, Gressens P, Foo R, Passemard S, Tan E-C, El Ghoulzi V, Shirahige K. ARCN1 mutations cause a recognizable craniofacial syndrome due to COPI-mediated transport defects. *Am J Hum Genet* 2016;99:451–9.
- Lines MA, Huang L, Schwartzentruber J, Douglas SL, Lynch DC, Beaulieu C, Guion-Almeida ML, Zechi-Ceide RM, Gener B, Gillissen-Kaesbach G, Nava C, Baujat G, Horn D, Kini U, Caliebe A, Alanay Y, Utine GE, Lev D, Kohlhasse J, Grix AW, Lohmann DR, Hehr U, Böhm D, Majewski J, Bulman DE, Wiczkorek D, Boycott KM, FORGE Canada Consortium. Haploinsufficiency of a spliceosomal GTPase encoded by Eftud2 causes mandibulofacial dysostosis with microcephaly. *Am J Hum Genet* 2012;90:369–77.
- Ostergaard P, Simpson MA, Mendola A, Vasudevan P, Connell FC, van Impel A, Moore AT, Loeys BL, Ghalamkarpour A, Onoufriadi A, Martinez-Corral I, Devery S, Leroy JG, van Laer L, Singer A, Bialer MG, McEntagart M, Quarrell O, Brice G, Trembath RC, Schulte-Merker S, Makinen T, Vikkula M, Mortimer PS, Mansour S, Jeffery S. Mutations in KIF11 cause autosomal-dominant microcephaly variably associated with congenital lymphedema and chorioretinopathy. *Am J Hum Genet* 2012;90:356–62.
- Boonsawat P, Joset P, Steindl K, Oneda B, Gogoll L, Azzarello-Burri S, Sheth F, Datar C, Verma IC, Puri RD, Zollino M, Bachmann-Gagescu R, Niedrist D, Papik M, Figueiro-Silva J, Masood R, Zweier M, Kraemer D, Lincoln S, Rodan L, Passemard S, Drunat S, Verloes A, Horn AHC, Sticht H, Steinfeld R, Plecko B, Latal B, Jenni O, Asadollahi R, Rauch A, Undiagnosed Diseases Network (UDN). Elucidation of the phenotypic spectrum and genetic landscape in primary and secondary microcephaly. *Genet Med* 2019;21:2043–58.
- Jayaraman D, Bae B-I, Walsh CA. The genetics of primary microcephaly. *Annu Rev Genomics Hum Genet* 2018;19:177–200.
- Bond J, Roberts E, Springell K, Lizarraga SB, Lizarraga S, Scott S, Higgins J, Hampshire DJ, Morrison EE, Leal GF, Silva EO, Costa SMR, Baralle D, Raponi M, Karbani G, Rashid Y, Jafri H, Bennett C, Corry P, Walsh CA, Woods CG. A centrosomal mechanism involving CDK5RAP2 and CENPJ controls brain size. *Nat Genet* 2005;37:353–5.
- Graser S, Stierhof Y-D, Nigg EA. Cep68 and Cep215 (CDK5RAP2) are required for centrosome cohesion. *J Cell Sci* 2007;120:4321–31.
- Barr AR, Kilmartin JV, Gergely F. Cdk5Rap2 functions in centrosome to spindle pole attachment and DNA damage response. *J Cell Biol* 2010;189:23–39.
- Fong K-W, Choi Y-K, Rattner JB, Qi RZ. Cdk5Rap2 is a pericentriolar protein that functions in centrosomal attachment of the γ -tubulin ring complex. *Mol Biol Cell* 2008;19:115–25.
- Megraw TL, Sharkey JT, Nowakowski RS. Cdk5Rap2 exposes the centrosomal root of microcephaly syndromes. *Trends Cell Biol* 2011;21:470–80.
- Buchman JJ, Durak O, Tsai L-H. Aspm regulates Wnt signaling pathway activity in the developing brain. *Genes Dev* 2011;25:1909–14.
- Lizarraga SB, Margossian SP, Harris MH, Campagna DR, Han A-P, Blevins S, Mudbhary R, Barker JE, Walsh CA, Fleming MD. Cdk5Rap2 regulates centrosome function and chromosome segregation in neuronal progenitors. *Development* 2010;137:1907–17.
- Issa L, Kraemer N, Rickert CH, Siffringer M, Ninnemann O, Stoltenberg-Diding G, Kaindl AM. Cdk5Rap2 expression during murine and human brain development correlates with pathology in primary autosomal recessive microcephaly. *Cereb Cortex* 2013;23:2245–60.
- Abdullah U, Farooq M, Mang Y, Marriam Bakhtiar S, Fatima A, Hansen L, Kjaer KW, Larsen LA, Faryal S, Tommerup N, Mahmood Baig S. A novel mutation in CDK5RAP2 gene causes primary microcephaly with speech impairment and sparse eyebrows in a consanguineous Pakistani family. *Eur J Med Genet* 2017;60:627–30.
- Ahmad I, Baig SM, Abdulkareem AR, Hussain MS, Sur I, Toliat MR, Nürnberg G, Dalibor N, Moawia A, Waseem SS, Asif M, Nagra H, Sher M, Khan MMA, Hassan I, Rehman SU, Thiele H, Altmüller J, Noegel AA, Nürnberg P. Genetic heterogeneity in Pakistani microcephaly families revisited. *Clin Genet* 2017;92:62–8.
- Alfares A, Alhufayti I, Alsabaie L, Alowain M, Almass R, Alfadhel M, Kaya N, Eyaid W. A new association between CDK5RAP2 microcephaly and congenital cataracts. *Ann Hum Genet* 2018;82:165–70.
- Hassan MJ, Khurshid M, Azeem Z, John P, Ali G, Chishti MS, Ahmad W. Previously described sequence variant in CDK5RAP2 gene in a Pakistani family with autosomal recessive primary microcephaly. *BMC Med Genet* 2007;8:58.
- Issa L, Mueller K, Seufert K, Kraemer N, Rosenkötter H, Ninnemann O, Buob M, Kaindl AM, Morris-Rosendahl DJ. Clinical and cellular features in patients with primary autosomal recessive microcephaly and a novel CDK5RAP2 mutation. *Orphanet J Rare Dis* 2013;8:59.
- Jouan L, Ouled Amar Bencheikh B, Daoud H, Dionne-Laporte A, Dobrzyniecka S, Spiegelman D, Rochefort D, Hince P, Szuto A, Lassonde M, Barbelanne M, Tsang WY, Dion PA, Théoret H, Rouleau GA, Wy T, Ga R. Exome sequencing identifies recessive CDK5RAP2 variants in patients with isolated agenesis of corpus callosum. *Eur J Hum Genet* 2016;24:607–10.
- Lancaster MA, Renner M, Martin C-A, Wenzel D, Bicknell LS, Hurler ME, Homfray T, Penninger JM, Jackson AP, Knoblich JA. Cerebral organoids model human brain development and microcephaly. *Nature* 2013;501:373–9.
- Li MH, Arndt K, Das S, Weiss EM, Wu Y, Gwal K, Shekdar KV, Zackai EH. Compound heterozygote CDK5RAP2 mutations in a Guatemalan/Honduran child with autosomal recessive primary microcephaly, failure to thrive and speech delay. *Am J Med Genet A* 2015;167:1414–7.
- Moynihan L, Jackson AP, Roberts E, Karbani G, Lewis I, Corry P, Turner G, Mueller RF, Lench NJ, Woods CG. A third novel locus for primary autosomal recessive microcephaly maps to chromosome 9q34. *Am J Hum Genet* 2000;66:724–7.
- Pagnamenta AT, Murray JE, Yoon G, Sadighi Akha E, Harrison V, Bicknell LS, Ajillogba K, Stewart H, Kini U, Taylor JC, Keays DA, Jackson AP, Knight SJA. A novel nonsense CDK5RAP2 mutation in a Somali child with primary microcephaly and sensorineural hearing loss. *Am J Med Genet A* 2012;158A:2577–82.
- Sukumaran SK, Stumpf M, Salamon S, Ahmad I, Bhattacharya K, Fischer S, Müller R, Altmüller J, Budde B, Thiele H, Tariq M, Malik NA, Nürnberg P, Baig SM, Hussain MS, Noegel AA. Cdk5Rap2 interaction with components of the Hippo signaling pathway may play a role in primary microcephaly. *Mol Genet Genomics* 2017;292:365–83.
- Tan CA, del Gaudio D, Dempsey MA, Arndt K, Botes S, Reeder A, Das S. Analysis of ASPM in an ethnically diverse cohort of 400 patient samples: perspectives of the molecular diagnostic laboratory. *Clin Genet* 2014;85:353–8.
- Yigit G, Brown KE, Kayserili H, Pohl E, Caliebe A, Zahnleiter D, Rosser E, Bögershausen N, Uyguner ZO, Altunoglu U, Nürnberg G, Nürnberg P, Rauch A, Li Y, Thiel CT, Wollnik

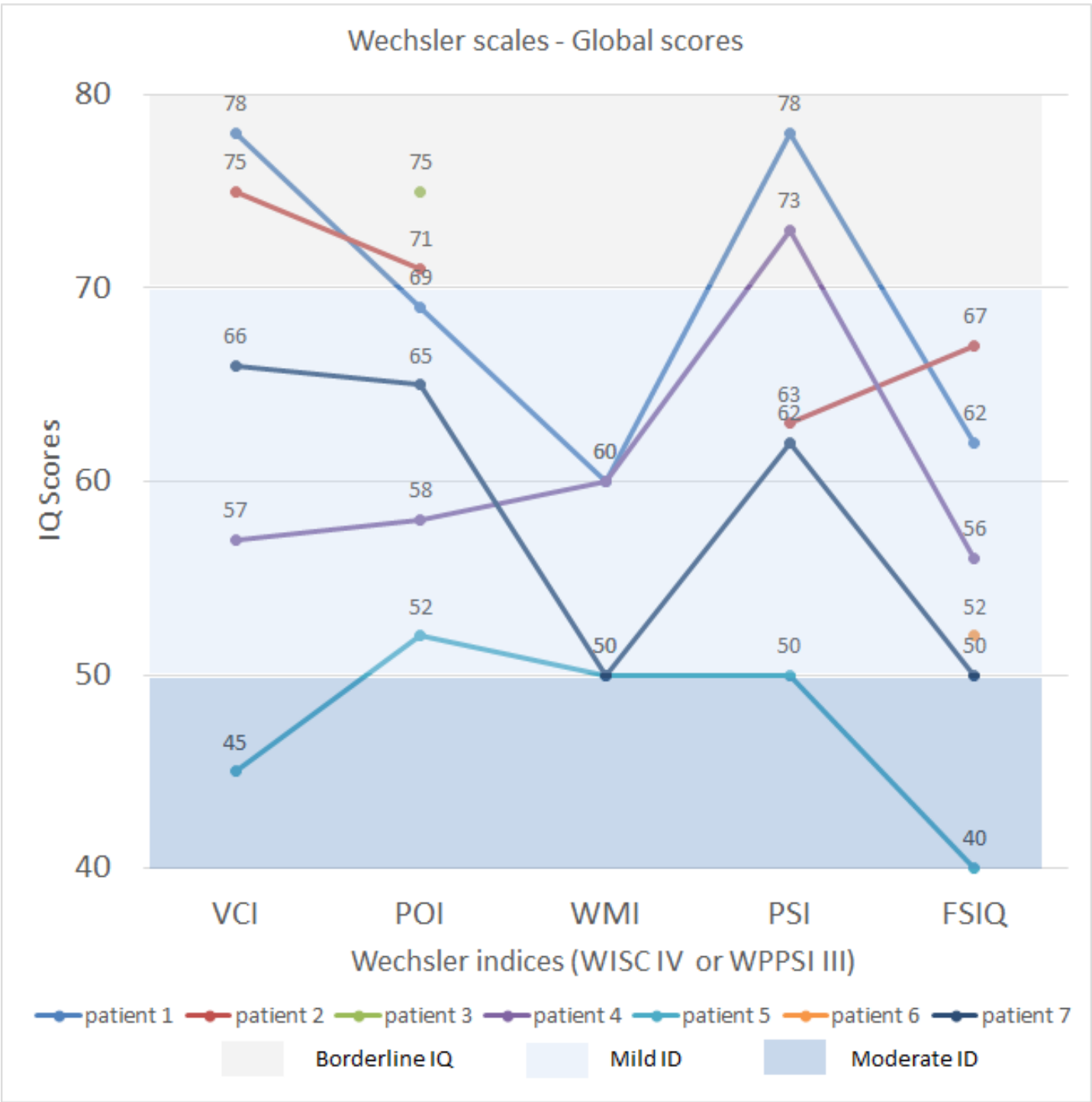
- B. Mutations in CDK5RAP2 cause Seckel syndrome. *Mol Genet Genomic Med* 2015;3:467–80.
- 30 Létard P, Drunat S, Vial Y, Duerinckx S, Ernault A, Amram D, Arpin S, Bertoli M, Busa T, Ceulemans B, Desir J, Doco-Fenzy M, Elalaoui SC, Devriendt K, Faivre L, Francannet C, Geneviève D, Gérard M, Gitiaux C, Julia S, Lebon S, Lubala T, Mathieu-Dramard M, Maurey H, Metreau J, Nasserredine S, Nizon M, Pierquin G, Pouvreau N, Rivier-Ringenbach C, Rossi M, Schaefer E, Sefiani A, Sigaudy S, Sznajer Y, Tunca Y, Guilmin Crepon S, Alberti C, Elmaleh-Bergès M, Benzacken B, Wollnick B, Woods CG, Rauch A, Abramowicz M, El Ghouzzi V, Gressens P, Verloes A, Passemard S. Autosomal recessive primary microcephaly due to ASPM mutations: an update. *Hum Mutat* 2018;39:319–32.
 - 31 Baala L, Briault S, Etchevers HC, Laumonnier F, Natiq A, Amiel J, Boddaert N, Picard C, Sbiti A, Asermouh A, Attié-Bitach T, Encha-Razavi F, Munnich A, Sefiani A, Lyonnet S. Homozygous silencing of T-box transcription factor EOMES leads to microcephaly with polymicrogyria and corpus callosum agenesis. *Nat Genet* 2007;39:454–6.
 - 32 Ahmed FN, Stence NV, Mirsky DM. Asymptomatic Interhypothalamic adhesions in children. *AJNR Am J Neuroradiol* 2016;37:726–9.
 - 33 Teissier N, Van Den Abbeele T, Sebag G, Elmaleh-Berges M. Computed tomography measurements of the normal and the pathologic cochlea in children. *Pediatr Radiol* 2010;40:275–83.
 - 34 Sennaroglu L, Saatci I. Unpartitioned versus incompletely partitioned cochleae: radiologic differentiation. *Otol Neurotol* 2004;25:520–9.
 - 35 Gilmore EC, Walsh CA. Genetic causes of microcephaly and lessons for neuronal development. *Wiley Interdiscip Rev Dev Biol* 2013;2:461–78.
 - 36 Passemard S, Perez F, Colin-Lemesre E, Rasika S, Gressens P, El Ghouzzi V. Golgi trafficking defects in postnatal microcephaly: The evidence for "Golgiopathies". *Prog Neurobiol* 2017;153:46–63.
 - 37 Whitehead MT, Vezina G. Interhypothalamic adhesion: a series of 13 cases. *AJNR Am J Neuroradiol* 2014;35:2002–6.
 - 38 Kakar N, Ahmad J, Morris-Rosendahl DJ, Altmüller J, Friedrich K, Barbi G, Nürnberg P, Kubisch C, Dobyns WB, Borck G. Stil mutation causes autosomal recessive microcephalic lobar holoprosencephaly. *Hum Genet* 2015;134:45–51.
 - 39 Paul A, Marlin S, Parodi M, Rouillon I, Guerlain J, Pingault V, Couloigner V, Garabedian EN, Denoyelle F, Loundon N. Unilateral sensorineural hearing loss: medical context and etiology. *Audiol Neurotol* 2017;22:83–8.
 - 40 Wentland CJ, Ronner EA, Basonbul RA, Pinnapureddy S, Mankarious L, Keamy D, Lee DJ, Cohen MS. Utilization of diagnostic testing for pediatric sensorineural hearing loss. *Int J Pediatr Otorhinolaryngol* 2018;111:26–31.
 - 41 Lim R, Brichth AM. Anatomical and physiological development of the human inner ear. *Hear Res* 2016;338:9–21.
 - 42 Everett LA, Glaser B, Beck JC, Idol JR, Buchs A, Heyman M, Adawi F, Hazani E, Nassir E, Baxevanis AD, Sheffield VC, Green ED. Pendred syndrome is caused by mutations in a putative sulphate transporter gene (PDS). *Nat Genet* 1997;17:411–22.
 - 43 Usami S, Abe S, Weston MD, Shinkawa H, Van Camp G, Kimberling WJ. Non-Syndromic hearing loss associated with enlarged vestibular aqueduct is caused by PDS mutations. *Hum Genet* 1999;104:188–92.
 - 44 Lenz DR, Avraham KB. Hereditary hearing loss: from human mutation to mechanism. *Hear Res* 2011;281:3–10.
 - 45 Scheidecker S, Etard C, Haren L, Stoetzel C, Hull S, Arno G, Plagnol V, Drunat S, Passemard S, Toutain A, Obringer C, Koob M, Geoffroy V, Marion V, Strähle U, Ostergaard P, Verloes A, Merdes A, Moore AT, Dollfus H. Mutations in TUBGCP4 alter microtubule organization via the γ -tubulin ring complex in autosomal-recessive microcephaly with chorioretinopathy. *Am J Hum Genet* 2015;96:666–74.
 - 46 Martin C-A, Ahmad I, Klingseisen A, Hussain MS, Bicknell LS, Leitch A, Nürnberg G, Toliat MR, Murray JE, Hunt D, Khan F, Ali Z, Tinschert S, Ding J, Keith C, Harley ME, Heyn P, Müller R, Hoffmann I, Cormier-Daire V, Dollfus H, Dupuis L, Bashamboo A, McElreavey K, Kariminejad A, Mendoza-Londono R, Moore AT, Saggar A, Schlechter C, Weleber R, Thiele H, Altmüller J, Höhn W, Hurler ME, Noegel AA, Baig SM, Nürnberg P, Jackson AP. Mutations in PLK4, encoding a master regulator of centriole biogenesis, cause microcephaly, growth failure and retinopathy. *Nat Genet* 2014;46:1283–92.
 - 47 Robitaille JM, Gillet RM, LeBlanc MA, Gaston D, Nightingale M, Mackley MP, Parkash S, Hathaway J, Thomas A, Ellis A, Traboulsi EI, Héon E, Roy M, Shalev S, Fernandez CV, MacGillivray C, Wallace K, Fahiminiya S, Majewski J, McMaster CR, Bedard K. Phenotypic overlap between familial exudative vitreoretinopathy and microcephaly, lymphedema, and chorioretinal dysplasia caused by KIF11 mutations. *JAMA Ophthalmol* 2014;132:1393–9.
 - 48 Zaqout S, Ravindran E, Stoltenburg-Didinge G, Kaindl AM. Congenital microcephaly-linked CDK5RAP2 affects eye development. *Ann Hum Genet* 2019. doi:10.1111/ahg.12343. [Epub ahead of print: 29 Jul 2019].
 - 49 Abdel-Salam GM, Vogt G, Halász A, Czeizel A. Microcephaly with normal intelligence, and chorioretinopathy. *Ophthalmic Genet* 1999;20:259–64.
 - 50 Garel C, Cont I, Alberti C, Josserand E, Moutard ML, Ducou le Pointe H. Biometry of the corpus callosum in children: MR imaging reference data. *AJNR Am J Neuroradiol* 2011;32:1436–43.

PATIENTS	REFERENCE	FAMILY	ORIGIN	CONSAQUINITY	AGE AT DIAGNOSIS (years)	Mutation 1	Mutation 2	PRENATAL FEATURES	SEX	OFC AT BIRTH (SD)	WEIGHT AT BIRTH (SD)	HEIGHT AT BIRTH (SD)	AGE AT TIME OF EXAMINATION (years)	OFC AT TIME OF EXAMINATION (DS)	WEIGHT AT TIME OF EXAMINATION (DS)	HEIGHT AT TIME OF EXAMINATION (DS)	BRAIN IMAGING	NEURODEVELOPMENTAL OUTCOME	EPILEPSY	OTHER SYMPTOMS
Patient #1	Moynihan, 2000/ Bond, 2005	#1	Pakistan	Yes	Not Provided	c.246T>A (p.Ser82*)	c.246T>A (p.Ser82*)	Not Provided	M	Not Provided	Not Provided	Not Provided	Not Provided	-6	Not Provided	Not Provided	Not performed	Mild intellectual disability	No	No
Patient #2	Moynihan, 2000/ Bond, 2005	#1	Pakistan	Yes	Not Provided	c.246T>A (p.Ser82*)	c.246T>A (p.Ser82*)	Not Provided	F	Not Provided	Not Provided	Not Provided	Not Provided	-8	0,0	0,0	Not performed	Moderate intellectual disability	Yes - rare tonic/clonic seizures	Profound congenital neurosensory deafness
Patient #3	Moynihan, 2000/ Bond, 2005	#1	Pakistan	Yes	Not Provided	c.246T>A (p.Ser82*)	c.246T>A (p.Ser82*)	Not Provided	F	Not Provided	Not Provided	Not Provided	Not Provided	Not Provided	Not Provided	Not Provided	Not performed	IQ 86	No	No
Patient #4	Heney, 1992/Moynihan, 2000/ Bond, 2005	#1	Pakistan	Yes	Not Provided	c.246T>A (p.Ser82*)	c.246T>A (p.Ser82*)	Not Provided	F	Not Provided	Not Provided	Not Provided	Not Provided	Not Provided	Not Provided	Not Provided	Not performed	IQ 89	No	Acute Lymphoblastic Leukemia causing death - skin areas of hypopigmentation
Patient #5	Bond, 2005	#2	Pakistan	Yes	Not Provided	c.4005-15A>G (p.E386fs*4)	c.4005-15A>G (p.E386fs*4)	Not Provided	F	Not Provided	Not Provided	Not Provided	Not Provided	-5	Not Provided	Not Provided	Not Provided	Moderate intellectual disability	Not Provided	Not Provided
Patient #6	Bond, 2005	#2	Pakistan	Yes	Not Provided	c.4005-15A>G (p.E386fs*4)	c.4005-15A>G (p.E386fs*4)	Not Provided	F	Not Provided	Not Provided	Not Provided	Not Provided	-7	Not Provided	Not Provided	Not Provided	Moderate intellectual disability	Not Provided	Not Provided
Patient #7	Hassan, 2007	#3	Pakistan	Yes	18-30	c.246T>A (p.Ser82*)	c.246T>A (p.Ser82*)	Not Provided	F	Not Provided	Not Provided	Not Provided	Not Provided	-4	Not Provided	Not Provided	Not Provided	IQ 51	No	No
Patient #8	Hassan, 2007	#3	Pakistan	Yes		c.246T>A (p.Ser82*)	c.246T>A (p.Ser82*)	Not Provided	F	Not Provided	Not Provided	Not Provided	Not Provided	-7	Not Provided	Not Provided	Not Provided	IQ 65	No	No
Patient #9	Hassan, 2007	#3	Pakistan	Yes		c.246T>A (p.Ser82*)	c.246T>A (p.Ser82*)	Not Provided	M	Not Provided	Not Provided	Not Provided	Not Provided	Not Provided	Not Provided	Not Provided	Not Provided	No	No	No
Patient #10	Hassan, 2007	#3	Pakistan	Yes		c.246T>A (p.Ser82*)	c.246T>A (p.Ser82*)	Not Provided	M	Not Provided	Not Provided	Not Provided	Not Provided	Not Provided	Not Provided	Not Provided	Not Provided	No	No	No
Patient #11	Pagnamenta, 2012	#4	Somalia	Yes	6	c.700G>T (p.Glu234*)	c.700G>T (p.Glu234*)	Not Provided	F	-3,7	-2,4	-3,7	6	-8,9	-1,1	-1,6	No abnormalities	Mild intellectual disability	No	severe gastric reflux - Moderate to severe bilateral neurosensory deafness - Slight hyperlaxity - Hypotonia
Patient #12	Issa, 2013	#5	Italy	Yes	Not Provided	c.4441C>T (p.Arg1481*)	c.4441C>T (p.Arg1481*)	Not Provided	M	Not Provided	0,5	Not Provided	5	-6	Not Provided	-4,1	Simplified gyral pattern (mostly frontal) - corpus callosum agenesis	IQ 69	No	Abdominal hernia - Skin areas of hyperpigmentation - Behavioral disorder - Tic disorder
Patient #13	Issa, 2013	#5	Italy	Yes	Not Provided	c.4441C>T (p.Arg1481*)	c.4441C>T (p.Arg1481*)	Not Provided	M	-3,5	-0,5	-0,5	2	-5	Not Provided	Not Provided	Simplified gyral pattern (mostly frontal) - corpus callosum and cerebellar hypoplasia	IQ 56	No	Skin areas of hyperpigmentation - Behavioral disorders
Patient #14	Lancaster, 2013	#6	Not Provided	No	Not Provided	c.4546G>T (p.Glu1516*)	c.4672C>T (p.Arg1558*)	Microcephaly	F	-6,5	-3,9	-5	3	-13,2	Not Provided	-6,7	Simplified gyral pattern	Not Provided	No	Neurosensory deafness
Patient #15	Tan, 2014	#7	Caucasian	No	5	c.524_528del(p.Gln175Argfs*42)	c.4005-1G>A (fs*)	Microcephaly	F	Not Provided	Not Provided	Not Provided	6	-8,9	-1,5	-3	No abnormalities	IQ 75	No	Asthma - Allergies - Sleep apnea
Patient #16	Li, 2015	#8	Hispanic	No	0,5	c.4441C>T (p.Arg1481*)	c.5227C>T (p.Gln1743*)	No	M	-3,1	-0,3	-1,5	Not Provided	Not Provided	Not Provided	Not Provided	Short corpus callosum	Not Provided	No	Failure to thrive (enteral nutrition)
Patient #17	Yigit, 2015	#9	Turkey	Yes	Not Provided	c.4005-9A>G (p.Arg1335Serfs*3)	c.4005-9A>G (p.Arg1335Serfs*3)	No	M	Not Provided	-2	Not Provided	9	-4	Not Provided	-3,2	Not Provided	Not Provided	No	Bone age delay -5th finger clinodactyly - 11 pairs of ribs
Patient #18	Yigit, 2015	#9	Turkey	Yes	Not Provided	c.4005-9A>G (p.Arg1335Serfs*3)	c.4005-9A>G (p.Arg1335Serfs*3)	Not Provided	F	Not Provided	Not Provided	Not Provided	10	-4	Not Provided	-3,4	No abnormalities	Mild intellectual disability	No	Congenital hip dislocation
Patient #19	Yigit, 2015	#10	Pakistan	Yes	Not Provided	c.383+1G>C(p.Lys129*)	c.383+1G>C(p.Lys129*)	Not Provided	F	Not Provided	-2	Not Provided	2	-6,2	Not Provided	-5	No abnormalities	Not Provided	No	Not Provided
Patient #20	Jouan, 2016	#11	Canada	No	53	c.280G>A (p.Gly94Arg)	c.3695A>G (p.Asn1232Ser)	No	F	Not Provided	Not Provided	Not Provided	53	1,0	Not Provided	0,0	Corpus callosum agenesis	IQ 84	No	Learning disabilities
Patient #21	Jouan, 2016	#11	Canada	No	52	c.280G>A (p.Gly94Arg)	c.3695A>G (p.Asn1232Ser)	No	F	Not Provided	Not Provided	Not Provided	52	-1,3	Not Provided	-0,5	Corpus callosum agenesis	IQ 78	No	Mutism - Intermittent ataxia
Patient #22	Jouan, 2016	#11	Canada	No	44	c.280G>A (p.Gly94Arg)	c.3695A>G (p.Asn1232Ser)	Not Provided	M	Not Provided	Not Provided	Not Provided	44	-1,3	Not Provided	0,5	Corpus callosum agenesis	IQ 77		Resolutive obsessive-compulsive disorder
Patient #23	Pagnamenta, 2016	#12	Not Provided	No	11	c.4604+1G>C	c.3097delG (p.V1033 fs*41)	Not Provided	M	Not Provided	Not Provided	Not Provided	11	-5,5	Not Provided	Not Provided	No abnormalities	developmental quotient: 45	No	Café-au-lait spots
Patient #24	Abdullah, 2017	#13	Pakistan	Yes	30	c.5127_5128dupGT (p.Ser1710CysfsTer22)	c.5127_5128dupGT (p.Ser1710CysfsTer22)	Not Provided	F	Not Provided	Not Provided	Not Provided	30	Not Provided	Not Provided	Not Provided		Severe intellectual disability - walking	No	
Patient #25	Abdullah, 2017	#13	Pakistan	Yes	32	c.5127_5128dupGT (p.Ser1710CysfsTer22)	c.5127_5128dupGT (p.Ser1710CysfsTer22)	Not Provided	M	Not Provided	Not Provided	Not Provided	32	Not Provided	Not Provided	Not Provided		Severe intellectual disability - walking	No	Moderate hearing impairment
Patient #26	Abdullah, 2017	#13	Pakistan	Yes	12	c.5127_5128dupGT (p.Ser1710CysfsTer22)	c.5127_5128dupGT (p.Ser1710CysfsTer22)	Not Provided	M	Not Provided	Not Provided	Not Provided	12	Not Provided	Not Provided	Not Provided		Moderate intellectual disability	No	
Patient #27	Abdullah, 2017	#13	Pakistan	Yes	8	c.5127_5128dupGT (p.Ser1710CysfsTer22)	c.5127_5128dupGT (p.Ser1710CysfsTer22)	Not Provided	F	Not Provided	Not Provided	Not Provided	8	Not Provided	Not Provided	Not Provided		Moderate intellectual disability	No	
Patient #28	Ahmad, 2017	#14	Pakistan	Yes	Not Provided	c.1279C>T (p.Arg427*)	c.1279C>T (p.Arg427*)	Not Provided	NP	Not Provided	Not Provided	Not Provided	Not Provided	Not Provided	Not Provided	Not Provided	Not Provided	Not Provided	Not Provided	Not Provided
Patient #29	Sukumaran, 2017	#15	Pakistan	Yes	16	c.4114C>T (p.Arg1372*)	c.4114C>T (p.Arg1372*)	Not Provided	F	Not Provided	Not Provided	Not Provided	16	-5	Not Provided	Not Provided		Mild intellectual disability		No
Patient #30	Sukumaran, 2017	#15	Pakistan	Yes	12	c.4114C>T (p.Arg1372*)	c.4114C>T (p.Arg1372*)	Not Provided	M	Not Provided	Not Provided	Not Provided	12	-9	Not Provided	Not Provided		Mild intellectual disability		No
Patient #31	Alfares, 2018	#16	Saudi Arabia	Yes	16	c.4055A>G (p.Glu1352Gly)	c.4055A>G (p.Glu1352Gly)	Not Provided	M	-2	1100	Not Provided	Not Provided	Not Provided	Not Provided	Not Provided	White matter abnormalities	Severe intellectual disability - non walking	Yes - epileptic encephalopathy with hypersarhythmia	Bilateral cataract - White matter abnormalities - Tetrapyramidal syndrome
Patient #32	Alfares, 2018	#16	Saudi Arabia	Yes	10	c.4055A>G (p.Glu1352Gly)	c.4055A>G (p.Glu1352Gly)	Not Provided	M	Not Provided	Not Provided	Not Provided	10	-2	-4	-4	moderate ventriculomegaly	Severe intellectual disability - non walking	Yes	Bilateral cataract - Tetrapyramidal syndrome - Dystonia
Patient #33	Alfares, 2018	#16	Saudi Arabia	Yes	8	c.4055A>G (p.Glu1352Gly)	c.4055A>G (p.Glu1352Gly)	Not Provided	F	Not Provided	Not Provided	Not Provided	8	-4	-4,5	-5	Thin corpus callosum	Severe intellectual disability - non walking	Yes - epileptic encephalopathy with hypersarhythmia	Bilateral cataract - Tetrapyramidal syndrome
Patient #34	Alfares, 2018	#16	Saudi Arabia	Yes	6	c.4055A>G (p.Glu1352Gly)	c.4055A>G (p.Glu1352Gly)	Intra uterine growth retardation	M	-2	1700	Not Provided	0,75	-4	Not Provided	Not Provided	Thin corpus callosum	Not Provided	Yes	Bilateral cataract - Hypospadias - Bilateral cryptorchidism - Cardiac congenital defect
Patient #35	Alfares, 2018	#17	Saudi Arabia	Not Provided	3	c.4672C>T p.(Arg1558*)	c.4672C>T p.(Arg1558*)	Not Provided	M	-3,5	Not Provided	Not Provided	Not Provided	Not Provided	Not Provided	Not Provided	Decreased cerebral volume	Intellectual disability	Yes	Cataract




Supplementary Figure 1





Supplementary Figure 3



ArriEre-plan

